



F. A. Davis Company

Always at your side...

ECG Notes

2nd Edition

Interpretation and Management Guide

Shirley A. Jones

*Waterproof
and
Reusable*

Includes...

- ✓ Wipe-Free Forms
- ✓ Expanded—Cardiac A&P
- ✓ ECG Basics
- ✓ 60+ Arrhythmias Analyzed
- ✓ Easy-to-Read 6-Second ECG Strips
- ✓ Emergency Meds
- ✓ New—Pediatric Emergency Meds
- ✓ Expanded—Emergency Skills
- ✓ 12-Lead Interpretation
- ✓ Expanded—Clinical Tips
- ✓ CPR Guidelines
- ✓ ACLS Protocols
- ✓ 50+ Test Yourself ECG Strips
- ✓ ECG Heart Rate Rulers
- ✓ New—PALS Protocols

Contacts • Phone/E-Mail

Name

Ph: e-mail:

Name

Ph: e-mail:

Name

Ph: e-mail:

Name

Ph: e-mail:

Name

Ph: e-mail:

Name

Ph: e-mail:

Name

Ph: e-mail:

Name

Ph: e-mail:

Name

Ph: e-mail:

Name

Ph: e-mail:

Name

Ph: e-mail:

Name

Ph: e-mail:

2nd Edition

ECG Notes

Interpretation and Management Guide

Shirley A. Jones, MS Ed, MHA, EMT-P

Purchase additional copies of this book at your health science bookstore or directly from F.A. Davis by shopping online at www.fadavis.com or by calling 800-323-3555 (US) or 800-665-1148 (CAN)

A Davis's Notes Book



F.A. Davis Company • Philadelphia

F. A. Davis Company
1915 Arch Street
Philadelphia, PA 19103
www.fadavis.com

Copyright © 2010 by F. A. Davis Company

All rights reserved. This book is protected by copyright. No part of it may be reproduced, stored in a retrieval system, or transmitted in any form or by any means, electronic, mechanical, photocopying, recording, or otherwise, without written permission from the publisher.

Printed in China by Imago

Last digit indicates print number: 10 9 8 7 6 5 4 3 2 1

Publisher, Nursing: Lisa B. Deitch

Director of Content Development: Darlene D. Pedersen

Project Editor: Christina C. Burns

Cover Design: Carolyn O'Brien

Reviewers: Jill M. Mayo, RN, MSN, ACLS; Jill Scott, RN, MSN, CCRN; Patricia Sweeney, MS, CRNP, FNP, BC; Barbara Tacinelli, RN, MA

As new scientific information becomes available through basic and clinical research, recommended treatments and drug therapies undergo changes. The author(s) and publisher have done everything possible to make this book accurate, up to date, and in accord with accepted standards at the time of publication. The author(s), editors, and publisher are not responsible for errors or omissions or for consequences from application of the book, and make no warranty, expressed or implied, in regard to the contents of the book. Any practice described in this book should be applied by the reader in accordance with professional standards of care used in regard to the unique circumstances that may apply in each situation. The reader is advised always to check product information (package inserts) for changes and new information regarding dose and contraindications before administering any drug. Caution is especially urged when using new or infrequently ordered drugs.

Authorization to photocopy items for internal or personal use, or the internal or personal use of specific clients, is granted by F. A. Davis Company for users registered with the Copyright Clearance Center (CCC) Transactional Reporting Service, provided that the fee of \$.25 per copy is paid directly to CCC, 222 Rosewood Drive, Danvers, MA 01923. For those organizations that have been granted a photocopy license by CCC, a separate system of payment has been arranged. The fee code for users of the Transactional Reporting Service is: 8036-2142-6/10 0 + \$.25.

- ✓ HIPAA Compliant
- ✓ OSHA Compliant

Waterproof and Reusable Wipe-Free Pages

**Write directly onto any page of *ECG Notes 2e*
with a ballpoint pen. Wipe old entries off
with an alcohol pad and reuse**

BASICS

ECGS

12-LEAD

MEDS

SKILLS

CPR

ACLS

PALS

**TEST
STRIPS**

TOOLS

Look for our other Davis's Notes titles, available now!

RNotes®: Nurse's Clinical Pocket Guide, 2nd edition
ISBN-13: 978-0-8036-1335-5

LPN Notes: Nurse's Clinical Pocket Guide, 2nd edition
ISBN-13: 978-0-8036-1767-4

DocuNotes: Nurse's Clinical Pocket Guide to Effective Documenting and Reporting
ISBN-13: 978-0-8036-2092-6

IV Med Notes: IV Administration Pocket Guide
ISBN-13: 978-0-8036-1466-8

IV Therapy Notes: Nurse's Clinical Pocket Guide
ISBN-13: 978-0-8036-1288-4

LabNotes: Guide to Lab & Diagnostic Tests, 2nd edition
ISBN-13: 978-0-8036-2138-1

MedNotes: Nurse's Pharmacology Pocket Guide, 2nd Edition
ISBN-13: 978-0-8036-1531-1

MedSurg Notes: Nurse's Clinical Pocket Guide, 2nd edition
ISBN-13: 978-0-8036-1868-8

NCLEX-RN® Notes: Core Review & Exam Prep
ISBN-13: 978-0-8036-1570-0

NutriNotes: Nutrition & Diet Therapy Pocket Guide
ISBN-13: 978-0-8036-1114-6

OB Peds Women's Health Notes: Nurse's Clinical Pocket Guide
ISBN-13: 978-0-8036-1466-6

PsychNotes: Clinical Pocket Guide, 2nd edition
ISBN-13: 978-0-8036-1853-4

Critical Care Notes: Clinical Pocket Guide
ISBN-13: 978-0-8036-2084-1

Assess Notes: Assessment and Diagnostic Reasoning
ISBN-13: 978-0-8036-1749-0

Also from Shirley A. Jones...

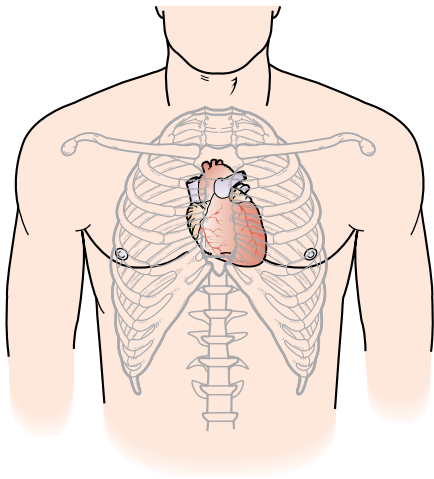
Pocket Anatomy & Physiology
ISBN-13: 978-0-8036-1824-4

ECG Success: Exercises in ECG Interpretation
ISBN-13: 978-0-8036-1577-9

For a complete list of Davis's Notes and other titles for health care providers, visit www.fadavis.com.

Anatomy of the Heart

The heart, a fist-sized muscular organ located in the mediastinum, is the central structure of the cardiovascular system. It is protected by the bony structures of the sternum anteriorly, the spinal column posteriorly, and the rib cage. The heart is roughly conical, with the base of the cone at the top of the heart and the apex (the pointed part) at the bottom. It is rotated slightly counterclockwise, with the apex tipped anteriorly so that the back surface of the heart actually lies over the diaphragm.

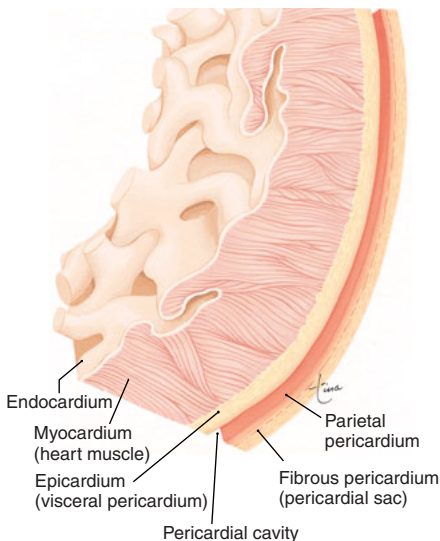


Location of the heart

♥ **Clinical Tip:** The cone-shaped heart has its tip (apex) just above the diaphragm to the left of the midline. This is why we may think of the heart as being on the left side—the strongest beat can be heard or felt there.

Layers of the Heart

The heart is composed of several different layers of tissue. Surrounding the heart itself is a protective sac called the pericardium. This double-walled sac has an inner, serous (visceral) layer and an outer, fibrous (parietal) layer. Between these layers is the pericardial cavity, which contains a small amount of lubricating fluid to prevent friction during heart contraction. The layers of the heart wall itself include the epicardium, or outermost layer; the myocardium, the thick middle layer of cardiac muscle; and the endocardium, the smooth layer of connective tissue that lines the inside of the heart.



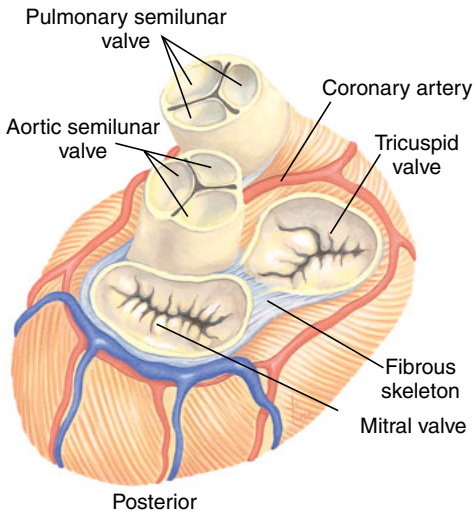
Layers of the heart

♥ **Clinical Tip:** The pericardial cavity contains a small amount of lubricating fluid to prevent friction during heart contraction.

Heart Valves

Properties of Heart Valves

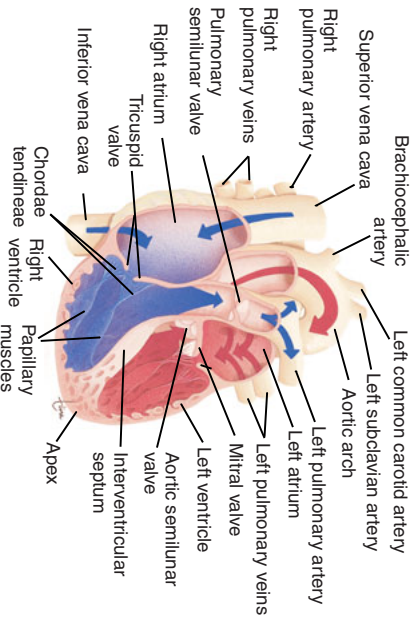
- Fibrous connective tissue prevents enlargement of valve openings and anchors valve flaps.
- Valve closure prevents backflow of blood during and after contraction.



Superior view with atria removed

Heart Chambers and Great Vessels

The heart is a hollow muscle with an internal skeleton of connective tissue that creates four separate chambers. The superior chambers of the heart are the right and left atria. Their primary function is to collect blood as it enters the heart and to help fill the lower chambers. The more thickly muscled lower chambers of the heart are the ventricles. These are the primary pumping chambers, the left having a thicker myocardial layer than the right.

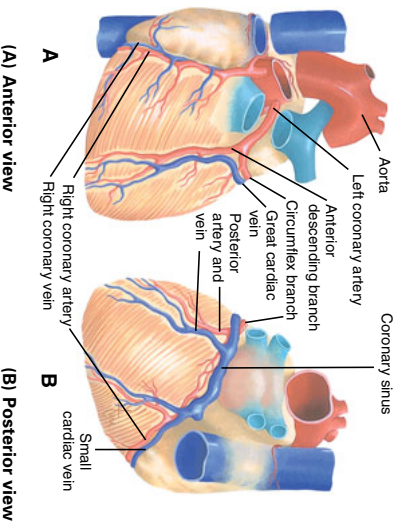


Heart—Anterior section (arrows show direction of blood flow)

Coronary Arteries and Veins

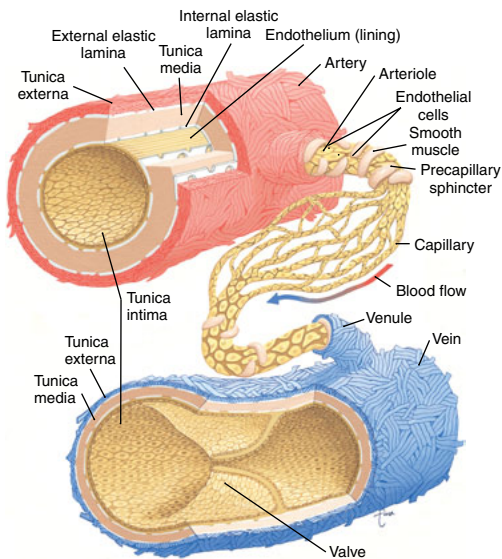
The coronary arteries and veins provide blood to the heart muscle and the electrical conduction system. The left and right coronary arteries are the first to branch off the aorta, just above the leaflets of the aortic valve.

5



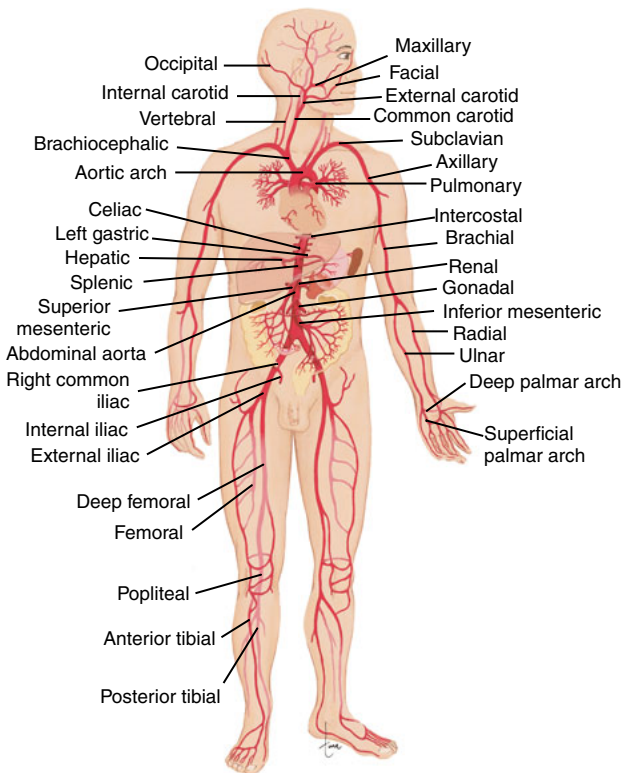
Anatomy of the Cardiovascular System

The cardiovascular system is a closed system consisting of the heart and all the blood vessels. Arteries and veins are connected by smaller structures that transport substances needed for cellular metabolism to body systems and remove the waste products of metabolism from those same tissues. Arteries carry blood away from the heart and, with the exception of the pulmonary arteries, transport oxygenated blood. Veins move blood toward the heart. With the exception of the pulmonary veins, they carry blood that is low in oxygen and high in carbon dioxide.

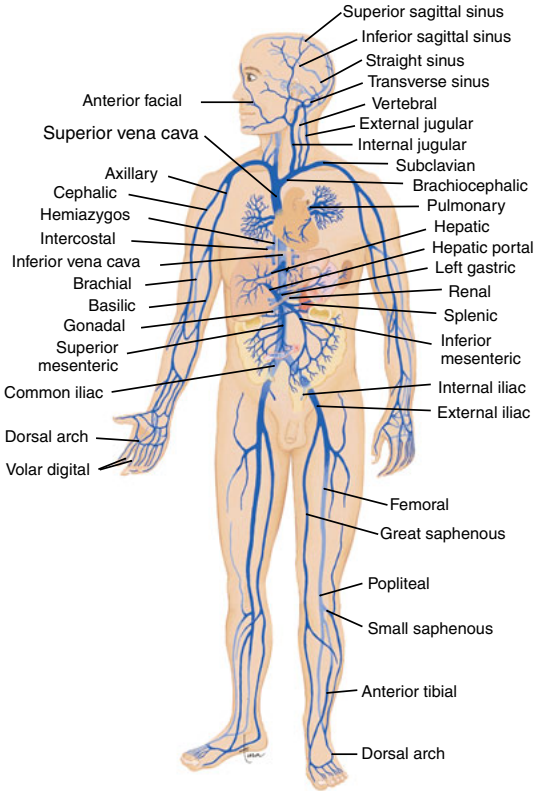


Blood vessels—Cross-section

Cardiovascular System—Major Arteries



Cardiovascular System—Major Veins



Physiology of the Heart

Normal blood flow through the heart begins at the right atrium, which receives systemic venous blood from the superior and inferior venae cavae. Blood passes from the right atrium, across the tricuspid valve, to the right ventricle. It is then pumped across the pulmonary valve into the pulmonary arteries.

Outside the heart, the left and right pulmonary arteries distribute blood to the lungs for gas exchange in the pulmonary capillaries. Oxygenated blood returns to the left atrium through the left and right pulmonary veins. After passing across the mitral valve, blood enters the left ventricle, where it is pumped across the aortic valve, through the aorta, into the coronary arteries and the peripheral circulation.

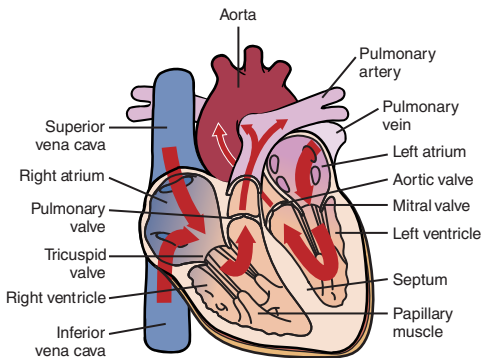
Mechanics of Heart Function

Process	Action
Cardiac cycle	Sequence of events in 1 heartbeat. Blood is pumped through the entire cardiovascular system.
Systole	Contraction phase—usually refers to ventricular contraction.
Diastole	Relaxation phase—the atria and ventricles are filling. Lasts longer than systole.
Stroke volume (SV)	Amount of blood ejected from either ventricle in a single contraction. Starling's Law of the Heart states that the degree of cardiac muscle stretch can increase the force of ejected blood. More blood filling the ventricles increases SV.
Cardiac output (CO)	Amount of blood pumped through the cardiovascular system per min. $CO = SV \times \text{Heart rate (HR)}$

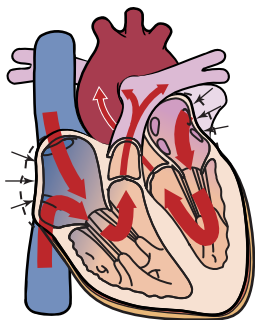
Properties of Cardiac Cells

Property	Ability
Automaticity	Generates electrical impulse independently, without involving the nervous system.
Excitability	Responds to electrical stimulation.
Conductivity	Passes or propagates electrical impulses from cell to cell.
Contractility	Shortens in response to electrical stimulation.

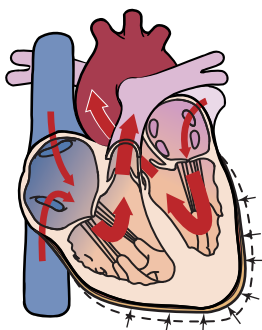
Systolic and Diastolic Phases in the Heart



Diastole



Atrial systolic phase



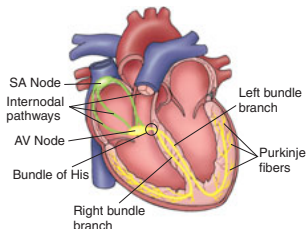
Ventricular systolic phase

Electrical Conduction System of the Heart

Electrophysiology

Structure	Function and Location
Sinoatrial (SA or sinus) node	Dominant pacemaker of the heart, located in upper portion of right atrium. Intrinsic rate 60–100 bpm.
Internodal pathways	Direct electrical impulses between the SA and AV nodes and spread them across the atrial muscle.
Atrioventricular (AV) node	Part of the AV junctional tissue, which includes some surrounding tissue plus the connected bundle of His. The AV node slows conduction, creating a slight delay before electrical impulses are carried to the ventricles. The intrinsic rate is 40–60 bpm.
Bundle of His	At the top of the interventricular septum, this bundle of fibers extends directly from the AV node and transmits impulses to the bundle branches.
Left bundle branch	Conducts electrical impulses to the left ventricle.
Right bundle branch	Conducts electrical impulses to the right ventricle.
Purkinje system	The bundle branches terminate with this network of fibers, which spread electrical impulses rapidly throughout the ventricular walls. The intrinsic rate is 20–40 bpm.

Continued



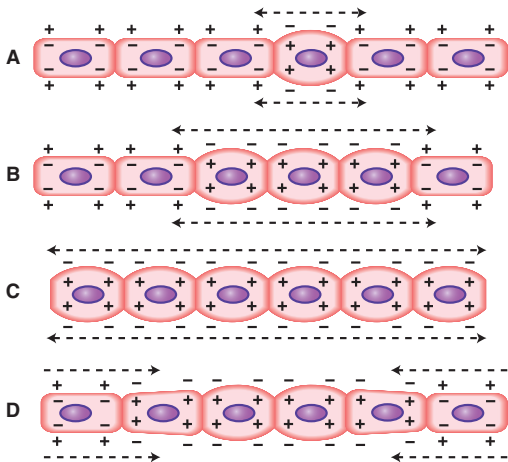
Conduction system of the heart

Electrical Conduction System of the Heart—cont'd

Electrophysiology

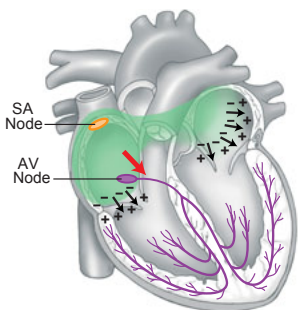
Action	Effect
Depolarization	The electrical charge of a cell is altered by a shift of electrolytes on either side of the cell membrane. This change stimulates muscle fiber to contract.
Repolarization	Chemical pumps re-establish an internal negative charge as the cells return to their resting state.

The Depolarization Process

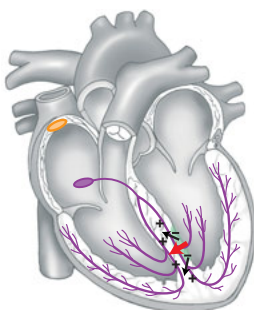


(A) A single cell has depolarized. (B) A wave propagates from cell to cell. (C) Wave propagation stops when all cells are depolarized. (D) Repolarization restores each cell's normal polarity.

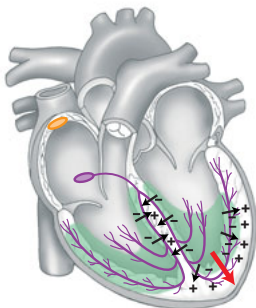
Progression of Depolarization Through the Heart



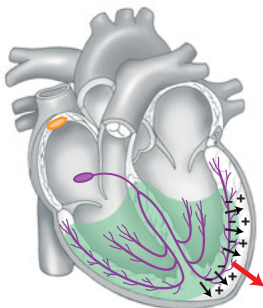
Atrial
depolarization



Septal
depolarization

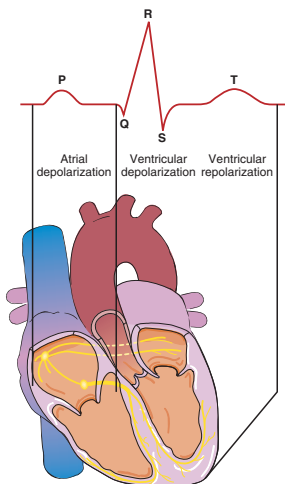


Apical
depolarization



Left ventricular
depolarization

Correlation of Depolarization and Repolarization With the ECG



♥ **Clinical Tip:** Mechanical and electrical functions of the heart are influenced by proper electrolyte balance. Important components of this balance are sodium, calcium, potassium, and magnesium.

The Electrocardiogram (ECG)

The body acts as a giant conductor of electrical current. Electrical activity that originates in the heart can be detected on the body's surface through an electrocardiogram (ECG). Electrodes are applied to the skin to measure voltage changes in the cells between the electrodes. These voltage changes are amplified and visually displayed on an oscilloscope and graph paper.

- An ECG is a series of waves and deflections recording the heart's electrical activity from a certain "view."
- Many views, each called a lead, monitor voltage changes between electrodes placed in different positions on the body.
- Leads I, II, and III are bipolar leads and consist of two electrodes of opposite polarity (positive and negative). The third (ground) electrode minimizes electrical activity from other sources.
- Leads aVR, aVL, and aVF are unipolar leads and consist of a single positive electrode and a reference point (with zero electrical potential) that lies in the center of the heart's electrical field.
- Leads V_1 – V_6 are unipolar leads and consist of a single positive electrode with a negative reference point found at the electrical center of the heart.
- An ECG tracing looks different in each lead because the recorded angle of electrical activity changes with each lead. Different angles allow a more accurate perspective than a single one would.
- The ECG machine can be adjusted to make any skin electrode positive or negative. The polarity depends on which lead the machine is recording.
- A cable attached to the patient is divided into several different-colored wires: three, four, or five for monitoring purposes, or ten for a 12-lead ECG.
- Incorrect placement of electrodes may turn a normal ECG tracing into an abnormal one.

♥ **Clinical Tip:** It is important to keep in mind that the ECG shows only electrical activity; it tells us nothing about how well the heart is working mechanically.

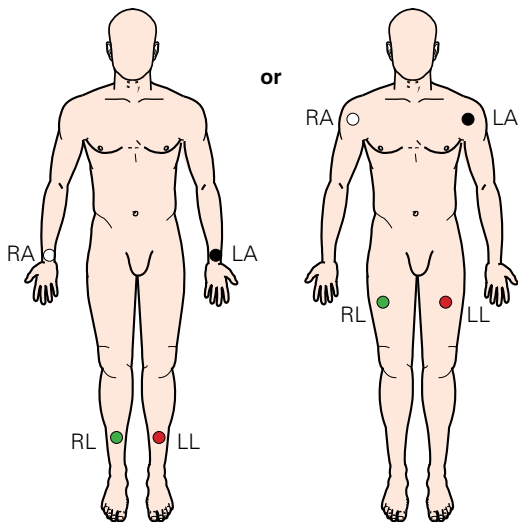
♥ **Clinical Tip:** Patients should be treated according to their symptoms, not merely their ECG.

♥ **Clinical Tip:** To obtain a 12-lead ECG, four wires are attached to each limb and six wires are attached at different locations on the chest. The total of ten wires provides 12 views (12 leads).

Limb Leads

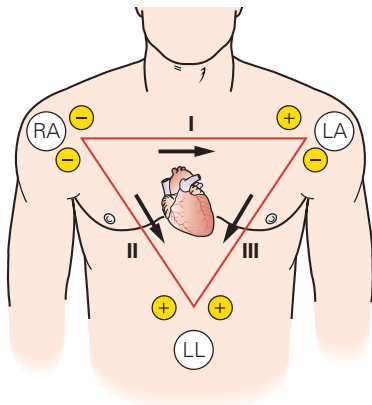
Electrodes are placed on the right arm (RA), left arm (LA), right leg (RL), and left leg (LL). With only four electrodes, six leads are viewed. These leads include the standard leads—I, II, and III—and the augmented leads—aVR, aVL, and aVF.

Standard Limb Lead Electrode Placement



Standard Limb Leads

Leads I, II, and III make up the standard leads. If electrodes are placed on the right arm, left arm, and left leg, three leads are formed. If an imaginary line is drawn between each of these electrodes, an axis is formed between each pair of leads. The axes of these three leads form an equilateral triangle with the heart in the center (Einthoven's triangle).



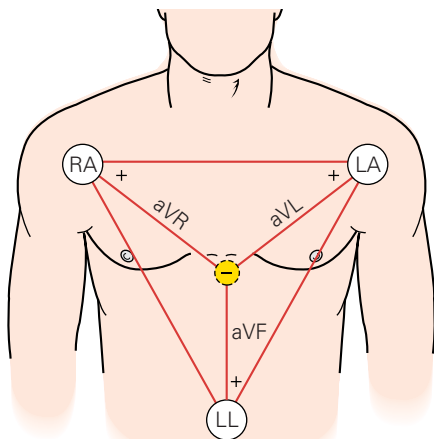
Elements of Standard Limb Leads

Lead	Positive Electrode	Negative Electrode	View of Heart
I	LA	RA	Lateral
II	LL	RA	Inferior
III	LL	LA	Inferior

♥ Clinical Tip: Lead II is commonly called a monitoring lead. It provides information on heart rate, regularity, conduction time, and ectopic beats. The presence or location of an acute myocardial infarction (MI) should be further diagnosed with a 12-lead ECG.

Augmented Limb Leads

Leads aVR, aVL, and aVF make up the augmented leads. Each letter of an augmented lead refers to a specific term: a = augmented; V = voltage; R = right arm; L = left arm; F = foot (the left foot).



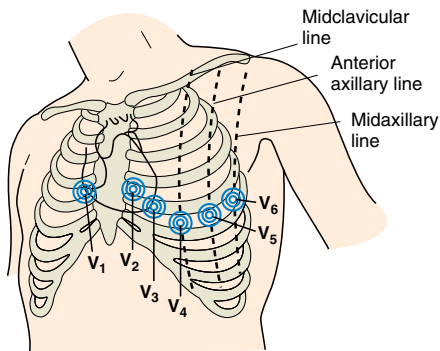
Elements of Augmented Limb Leads

Lead	Positive Electrode	View of Heart
aVR	RA	None
aVL	LA	Lateral
aVF	LL	Inferior

Chest Leads

Standard Chest Lead Electrode Placement

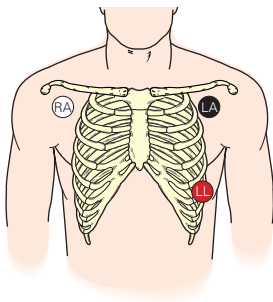
The chest leads are identified as V_1 , V_2 , V_3 , V_4 , V_5 , and V_6 . Each electrode placed in a "V" position is positive.



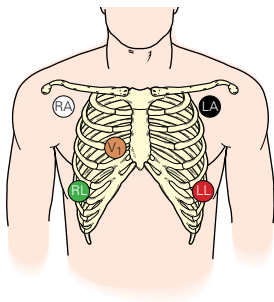
Elements of Chest Leads

Lead	Positive Electrode Placement	View of Heart
V_1	4th Intercostal space to right of sternum	Septum
V_2	4th Intercostal space to left of sternum	Septum
V_3	Directly between V_2 and V_4	Anterior
V_4	5th Intercostal space at left midclavicular line	Anterior
V_5	Level with V_4 at left anterior axillary line	Lateral
V_6	Level with V_5 at left midaxillary line	Lateral

Electrode Placement Using a 3-Wire Cable



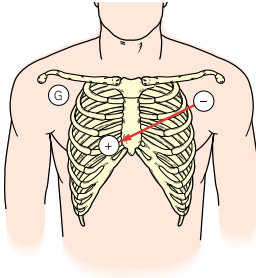
Electrode Placement Using a 5-Wire Cable



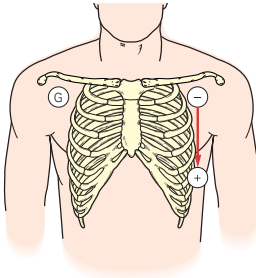
♥ **Clinical Tip:** Five-wire telemetry units are commonly used to monitor leads I, II, III, aVR, aVL, aVF, and V₁ in critical care settings.

Modified Chest Leads

- Modified chest leads (MCL) are useful in detecting bundle branch blocks and premature beats.
- Lead MCL_1 simulates chest lead V_1 and views the ventricular septum.
- Lead MCL_6 simulates chest lead V_6 and views the lateral wall of the left ventricle.



Lead MCL_1 electrode placement

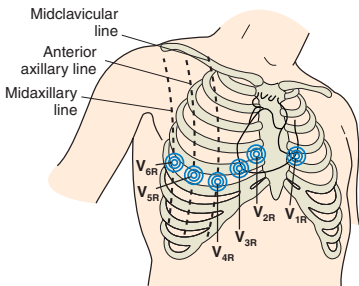


Lead MCL_6 electrode placement

♥ **Clinical Tip:** Write on the rhythm strip which simulated lead was used.

The Right-sided 12-Lead ECG

- The limb leads are placed as usual but the chest leads are a mirror image of the standard 12-lead chest placement.
- The ECG machine cannot recognize that the leads have been reversed. It will still print "V₁-V₆" next to the tracing. Be sure to cross this out and write the new lead positions on the ECG paper.



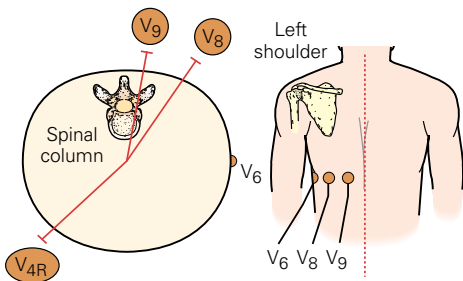
The Right-sided 12-Lead ECG

Chest Leads	Position
V _{1R}	4th Intercostal space to left of sternum
V _{2R}	4th Intercostal space to right of sternum
V _{3R}	Directly between V _{2R} and V _{4R}
V _{4R}	5th Intercostal space at right midclavicular line
V _{5R}	Level with V _{4R} at right anterior axillary line
V _{6R}	Level with V _{5R} at right midaxillary line

♥ **Clinical Tip:** Patients with an acute inferior MI should have right-sided ECGs to assess for possible right ventricular infarction.

The 15-Lead ECG

Areas of the heart that are not well visualized by the six chest leads include the wall of the right ventricle and the posterior wall of the left ventricle. A 15-lead ECG, which includes the standard 12 leads plus leads V_{4R} , V_{8r} , and V_9 , increases the chance of detecting an MI in these areas.

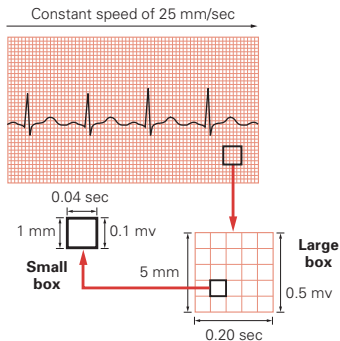


The 15-Lead ECG

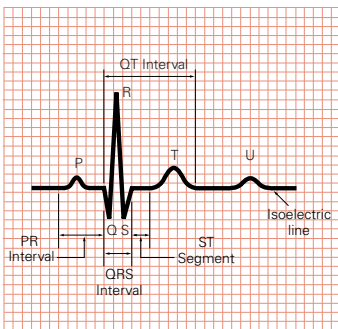
Chest Leads	Electrode Placement	View of Heart
V_{4R}	5th Intercostal space in right anterior midclavicular line	Right ventricle
V_8	Posterior 5th intercostal space in left midscapular line	Posterior wall of left ventricle
V_9	Directly between V_8 and spinal column at posterior 5th intercostal space	Posterior wall of left ventricle

♥ **Clinical Tip:** Use a 15-lead ECG when the 12-lead is normal but the history is still suggestive of an acute infarction.

Recording of the ECG



Components of an ECG Tracing



Electrical Activity

Term	Definition
Wave	A deflection, either positive or negative, away from the baseline (isoelectric line) of the ECG tracing
Complex	Several waves
Segment	A straight line between waves or complexes
Interval	A segment and a wave

♥ Clinical Tip: Between waves and cycles, the ECG records a baseline (isoelectric line), which indicates the absence of net electrical activity.

Electrical Components

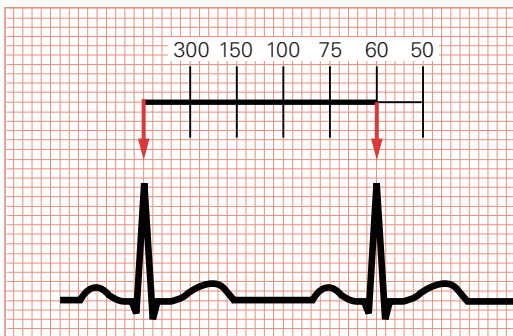
Deflection	Description
P Wave	First wave seen Small rounded, upright (positive) wave indicating atrial depolarization (and contraction)
PR Interval	Distance between beginning of P wave and beginning of QRS complex Measures time during which a depolarization wave travels from the atria to the ventricles
QRS Complex	Three deflections following P wave Indicates ventricular depolarization (and contraction) Q Wave: First negative deflection R Wave: First positive deflection S Wave: First negative deflection after R wave
ST Segment	Distance between S wave and beginning of T wave Measures time between ventricular depolarization and beginning of repolarization
T Wave	Rounded upright (positive) wave following QRS Represents ventricular repolarization
QT Interval	Distance between beginning of QRS to end of T wave Represents total ventricular activity
U Wave	Small rounded, upright wave following T wave Most easily seen with a slow HR Represents repolarization of Purkinje fibers

Methods for Calculating Heart Rate

Heart rate is the number of times the heart beats per minute (bpm). On an ECG tracing, bpm is usually calculated as the number of QRS complexes. Included are extra beats, such as premature ventricular contractions (PVC), premature atrial contractions (PAC), and premature junctional contractions (PJC). The rate is measured from the R-R interval, the distance between one R wave and the next. If the atrial rate (the number of P waves) and the ventricular rate (the number of QRS complexes) vary, the analysis may show them as different rates, one atrial and one ventricular. The method chosen to calculate HR varies according to rate and regularity on the ECG tracing.

Method 1: Count Large Boxes

Regular rhythms can be quickly determined by counting the number of large graph boxes between two R waves. That number is divided into 300 to calculate bpm. The rates for the first one to six large boxes can be easily memorized. Remember: $60 \text{ sec/min} \div 0.20 \text{ sec/large box} = 300 \text{ large boxes/min}$.



Counting large boxes for heart rate. The rate is 60 bpm.

Method 2: Count Small Boxes


The most accurate way to measure a regular rhythm is to count the number of small boxes between two R waves. That number is divided into 1500 to calculate bpm. Remember: $60 \text{ sec/min} \div 0.04 \text{ sec/small box} = 1500$ small boxes/min.

Examples: If there are three small boxes between two R waves: $1500/3 = 500$ bpm.

If there are five small boxes between two R waves: $1500/5 = 300$ bpm.

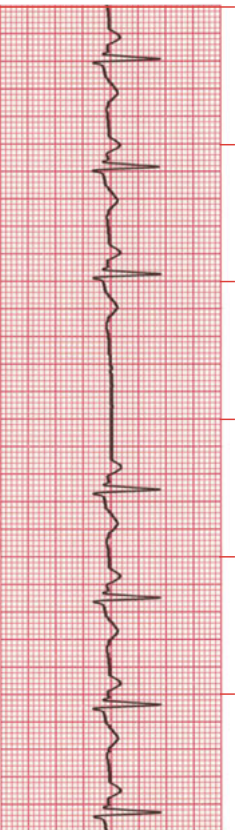
Methods 1 and 2 for Calculating Heart Rate

Number of Large Boxes	Rate/Min	Number of Small Boxes	Rate/Min
1	300	2	750
2	150	3	500
3	100	4	375
4	75	5	300
5	60	6	250
6	50	7	214
7	43	8	186
8	38	9	167
9	33	10	150
10	30	11	136
11	27	12	125
12	25	13	115
13	23	14	107
14	21	15	100
15	20	16	94

 **Clinical Tip:** Approximate rate/min is rounded to the next-highest number.

Method 3: Six-Second ECG Rhythm Strip

The best method for measuring irregular heart rates with varying R-R intervals is to count the number of R waves in a 6-sec strip (including extra beats such as PVCs, PACs, and PJCs) and multiply by 10. This gives the average number of beats per minute.



Using a 6-sec ECG rhythm strip to calculate heart rate: $7 \times 10 = 70$ bpm.

♥ **Clinical Tip:** If a rhythm is extremely irregular, it is best to count the number of R-R intervals per 60 sec (1 min).

ECG Interpretation

Analyzing a Rhythm

Component	Characteristic
Rate	The bpm is commonly the ventricular rate If atrial and ventricular rates differ, as in a 3rd-degree block, measure both rates Normal: 60–100 bpm Slow (bradycardia): <60 bpm Fast (tachycardia): >100 bpm
Regularity	Measure R-R intervals and P-P intervals Regular: Intervals consistent Regularly irregular: Repeating pattern Irregular: No pattern
P Waves	If present: Same in size, shape, position? Does each QRS have a P wave? Normal: Upright (positive) and uniform Inverted: Negative Notched: P' None: Rhythm is junctional or ventricular
PR Interval	Constant: Intervals are the same Variable: Intervals differ Normal: 0.12–0.20 sec and constant
QRS Interval	Normal: 0.06–0.10 sec Wide: >0.10 sec None: Absent
QT Interval	Beginning of QRS complex to end of T wave Varies with HR Normal: Less than half the RR interval
Dropped beats	Occur in AV blocks Occur in sinus arrest
Pause	Compensatory: Complete pause following a premature atrial contraction (PAC), premature junctional contraction (PJC), or premature ventricular contraction (PVC) Noncompensatory: Incomplete pause following a PAC, PJC, or PVC

Continued

Analyzing a Rhythm—cont'd

Component	Characteristic
QRS Complex grouping	Bigeminy: Repeating pattern of normal complex followed by a premature complex Trigeminy: Repeating pattern of 2 normal complexes followed by a premature complex Quadrigeminy: Repeating pattern of 3 normal complexes followed by a premature complex Couplet: 2 Consecutive premature complexes Triplet: 3 Consecutive premature complexes

Classification of Arrhythmias

Heart Rate	Classification
Slow	Bradycardia
Fast	Tachycardia
Absent	Pulseless arrest

Normal Heart Rate (bpm)

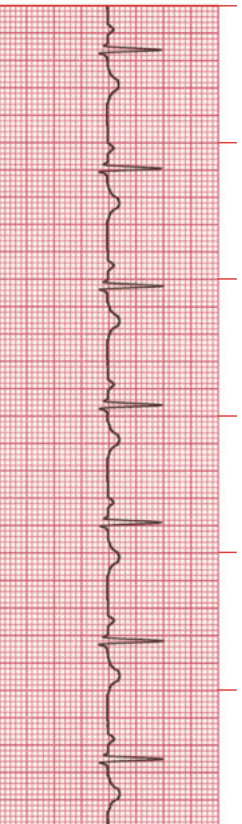Age	Awake Rate	Mean	Sleeping Rate
Newborn to 3 months	85–205	140	80–160
3 months to 2 years	100–190	130	75–160
2 to 10 years	60–140	80	60–90
>10 years	60–100	75	50–90

Notes:

Sinoatrial (SA) Node Arrhythmias

- Upright P waves all look similar. **Note: All ECG strips in Tab 2 were recorded in Lead II.**
- PR intervals and QRS complexes are of normal duration.

Normal Sinus Rhythm (NSR)



Rate: Normal (60–100 bpm)

Rhythm: Regular

P Waves: Normal (upright and uniform)

PR Interval: Normal (0.12–0.20 sec)

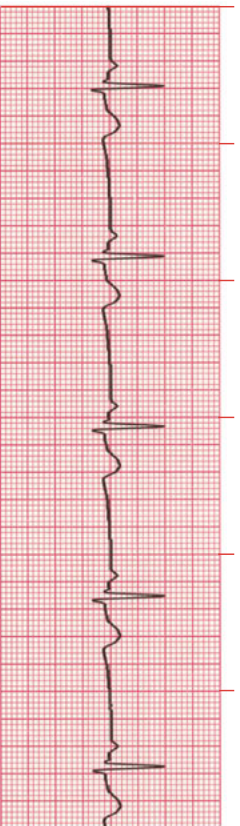QRS: Normal (0.06–0.10 sec)

♥ **Clinical Tip:** A normal ECG does not exclude heart disease.

♥ **Clinical Tip:** This rhythm is generated by the sinus node and its rate is within normal limits (60–80 bpm).

Sinus Bradycardia

- The SA node discharges more slowly than in NSR.



33

Rate: Slow (<60 bpm)

Rhythm: Regular

P Waves: Normal (upright and uniform)

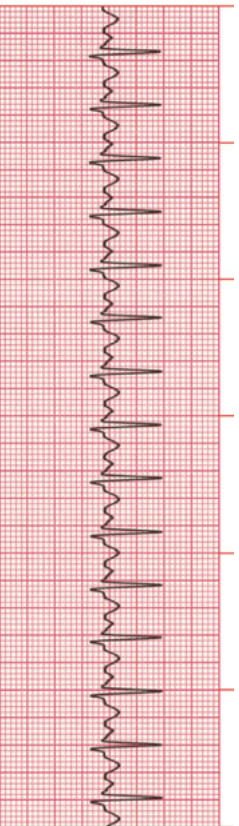
PR Interval: Normal (0.12–0.20 sec)

QRS: Normal (0.06–0.10 sec)

♥ **Clinical Tip:** Sinus bradycardia is normal in athletes and during sleep. In acute MI, it may be protective and beneficial or the slow rate may compromise cardiac output. Certain medications, such as beta blockers, may also cause sinus bradycardia.

Sinus Tachycardia

- The SA node discharges more frequently than in NSR.



Rate: Fast (>100 bpm)

Rhythm: Regular

P Waves: Normal (upright and uniform)

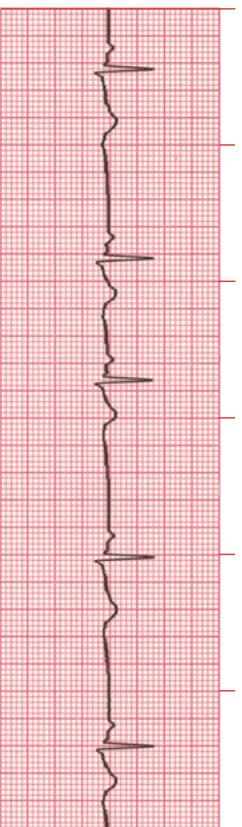
PR Interval: Normal (0.12–0.20 sec)

QRS: Normal (0.06–0.10 sec)

♥ **Clinical Tip:** Sinus tachycardia may be caused by exercise, anxiety, fever, hypoxemia, hypovolemia, or cardiac failure.

Sinus Arrhythmia

- The SA node discharges irregularly.
- The R-R interval is irregular.



35

Rate: Usually normal (60–100 bpm); frequently increases with inspiration and decreases with expiration; may be <60 bpm

Rhythm: Irregular; varies with respiration; difference between shortest RR and longest RR intervals is >0.12 sec

P Waves: Normal (upright and uniform)

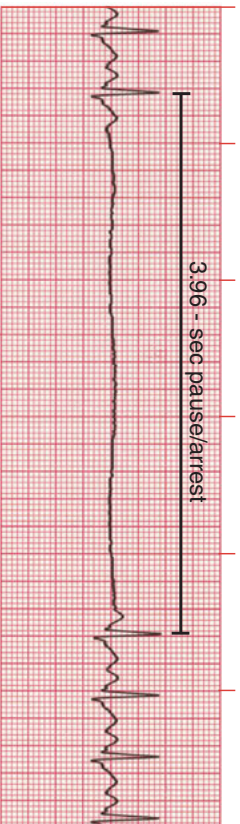
PR Interval: Normal (0.12–0.20 sec)

QRS: Normal (0.06–0.10 sec)

♥ **Clinical Tip:** The pacing rate of the SA node varies with respiration, especially in children and elderly people.

Sinus Pause (Sinus Arrest)

- The SA node fails to discharge and then resumes.
- Electrical activity resumes either when the SA node resets itself or when a slower latent pacemaker begins to discharge.
- The pause (arrest) time interval is not a multiple of the normal PP interval.



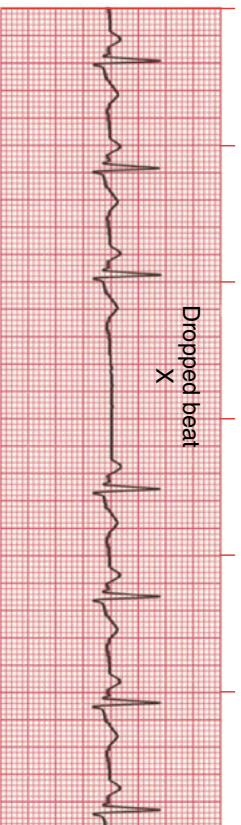
36

- ♥ **Rate:** Normal to slow; determined by duration and frequency of sinus pause (arrest)
- ♥ **Rhythm:** Irregular whenever a pause (arrest) occurs
- ♥ **P Waves:** Normal (upright and uniform) except in areas of pause (arrest)
- ♥ **PR Interval:** Normal (0.12–0.20 sec)
- ♥ **QRS:** Normal (0.06–0.10 sec)

♥ **Clinical Tip:** Cardiac output may decrease, causing syncope or dizziness.

Sinoatrial (SA) Block

- The block occurs in some multiple of the PP interval.
- After the dropped beat, cycles continue on time.



Rate: Normal to slow; determined by duration and frequency of SA block

Rhythm: Irregular whenever an SA block occurs

P Waves: Normal (upright and uniform) except in areas of dropped beats

PR Interval: Normal (0.12–0.20 sec)

QRS: Normal (0.06–0.10 sec)

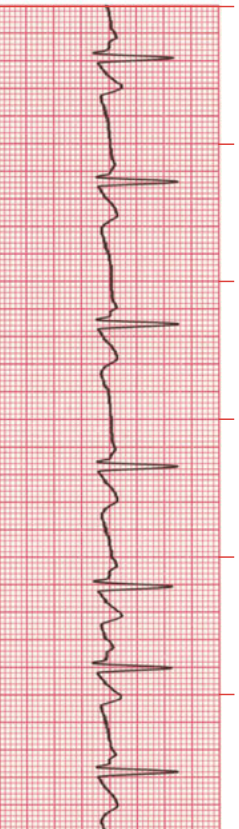
♥ **Clinical Tip:** Cardiac output may decrease, causing syncope or dizziness.

Atrial Arrhythmias

- P waves differ in appearance from sinus P waves.
- QRS complexes are of normal duration if no ventricular conduction disturbances are present.

Wandering Atrial Pacemaker (WAP)

- Pacemaker site transfers from the SA node to other latent pacemaker sites in the atria and the AV junction and then moves back to the SA node.



Rate: Normal (60–100 bpm)

Rhythm: Irregular

P Waves: At least three different forms, determined by the focus in the atria

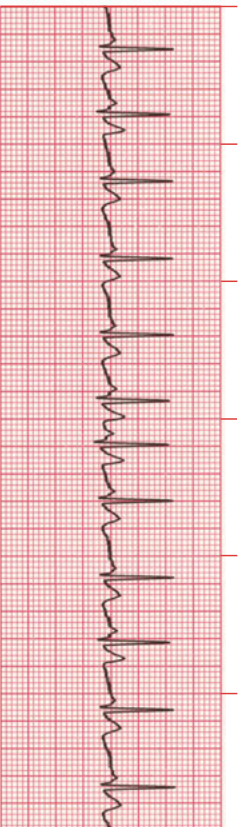
PR Interval: Variable; determined by focus

QRS: Normal (0.06–0.10 sec)

♥ **Clinical Tip:** WAP may occur in normal hearts as a result of fluctuations in vagal tone.

Multifocal Atrial Tachycardia (MAT)

- This form of WAP is associated with a ventricular response >100 bpm.
- MAT may be confused with atrial fibrillation (A-fib); however, MAT has a visible P wave.



39

Rate: Fast (>100 bpm)

Rhythm: Irregular

P Wave: At least three different forms, determined by the focus in the atria

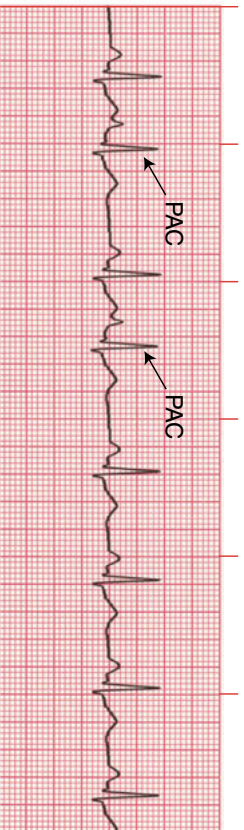
PR Interval: Variable; determined by focus

QRS: Normal (0.06–0.10 sec)

♥ **Clinical Tip:** MAT is commonly seen in patients with chronic obstructive pulmonary disease (COPD) but may also occur in an acute MI.

Premature Atrial Contraction (PAC)

- A single contraction occurs earlier than the next expected sinus contraction.
- After the PAC, sinus rhythm usually resumes.



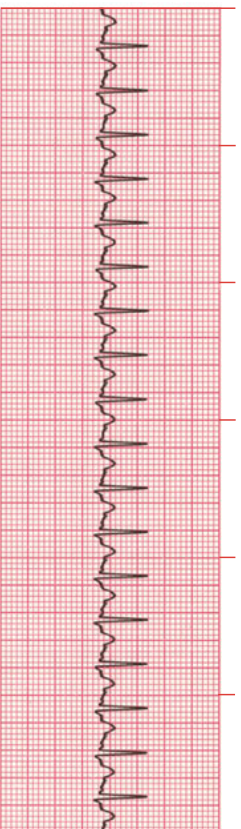
40

- **Rate:** Depends on rate of underlying rhythm
- **Rhythm:** Irregular whenever a PAC occurs
- **P Waves:** Present; in the PAC, may have a different shape
- **PR Interval:** Varies in the PAC; otherwise normal (0.12–0.20 sec)
- **QRS:** Normal (0.06–0.10 sec)

♥ **Clinical Tip:** In patients with heart disease, frequent PACs may precede paroxysmal supraventricular tachycardia (PSVT), atrial fibrillation (A-fib), or atrial flutter (A-flutter).

Atrial Tachycardia

- A rapid atrial rate overrides the SA node and becomes the dominant pacemaker.
- Some ST segment and T wave abnormalities may be present.



41

Rate: 150–250 bpm

Rhythm: Regular

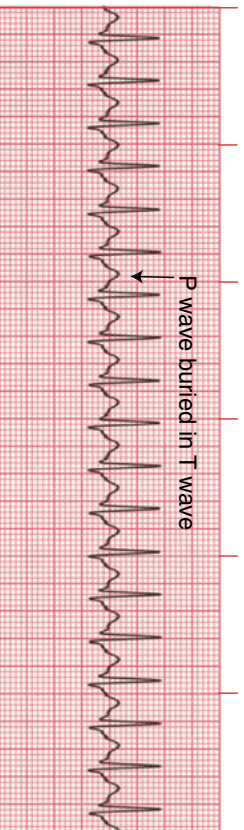
P Waves: Normal (upright and uniform) but differ in shape from sinus P waves

PR Interval: May be short (<0.12 sec) in rapid rates

QRS: Normal (0.06–0.10 sec) but can be aberrant at times

Supraventricular Tachycardia (SVT)

- This arrhythmia has such a fast rate that the P waves may not be seen.



Rate: 150–250 bpm

Rhythm: Regular

P Waves: Frequently buried in preceding T waves and difficult to see

PR Interval: Usually not possible to measure

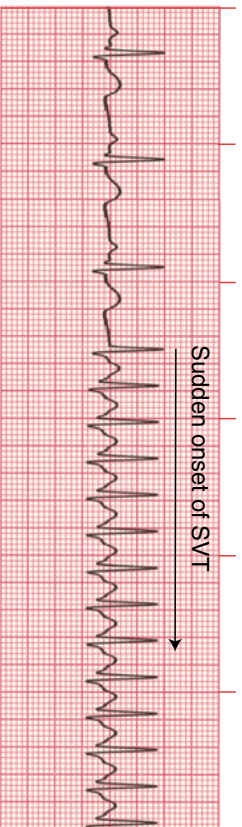QRS: Normal (0.06–0.10 sec) but may be wide if abnormally conducted through ventricles

- ♥ **Clinical Tip:** SVT may be related to caffeine intake, nicotine, stress, or anxiety in healthy adults.
- ♥ **Clinical Tip:** Some patients may experience angina, hypotension, light-headedness, palpitations, and intense anxiety.

Paroxysmal Supraventricular Tachycardia (PSVT)

- PSVT is a rapid rhythm that starts and stops suddenly.
- For accurate interpretation, the beginning or end of the PSVT must be seen.
- PSVT is sometimes called paroxysmal atrial tachycardia (PAT).

43



Rate: 150–250 bpm

Rhythm: Irregular

P Waves: Frequently buried in preceding T waves and difficult to see

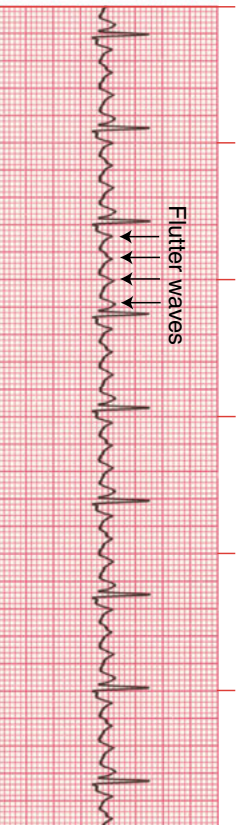
PR Interval: Usually not possible to measure

QRS: Normal (0.06–0.10 sec) but may be wide if abnormally conducted through ventricles

♥ **Clinical Tip:** The patient may feel palpitations, dizziness, lightheadedness, or anxiety.

Atrial Flutter (A-flutter)

- AV node conducts impulses to the ventricles at a ratio of 2:1, 3:1, 4:1, or greater (rarely 1:1).
- The degree of AV block may be consistent or variable.

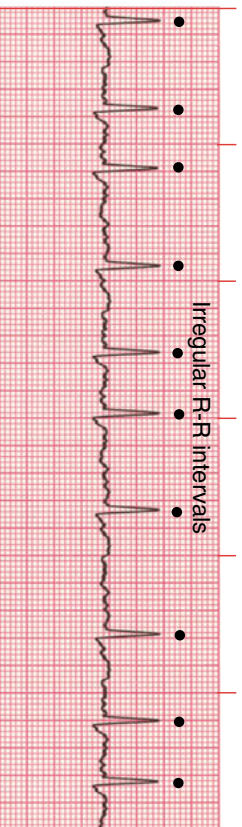


44

- ♥ **Rate:** Atrial: 250–350 bpm; ventricular: variable
- ♥ **Rhythm:** Atrial: regular; ventricular: variable
- ♥ **P Waves:** Flutter waves have a saw-toothed appearance; some may be buried in the QRS and not visible
- ♥ **PR Interval:** Variable
- ♥ **QRS:** Usually normal (0.06–0.10 sec), but may appear widened if flutter waves are buried in QRS
- ♥ **Clinical Tip:** A-flutter may be the first indication of cardiac disease.
- ♥ **Clinical Tip:** Signs and symptoms depend on ventricular response rate.

Atrial Fibrillation (A-fib)

- Rapid, erratic electrical discharge comes from multiple atrial ectopic foci.
- No organized atrial depolarization is detectable.



Rate: Atrial: ≥ 350 bpm; ventricular: variable

Rhythm: Irregular

P Waves: No true P waves; chaotic atrial activity

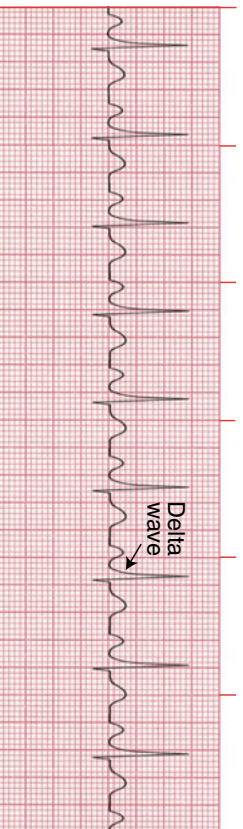
PR Interval: None

QRS: Normal (0.06–0.10 sec)

- ♥ **Clinical Tip:** A-fib is usually a chronic arrhythmia associated with underlying heart disease.
- ♥ **Clinical Tip:** Signs and symptoms depend on ventricular response rate.

Wolff-Parkinson-White (WPW) Syndrome

- In WPW, an accessory conduction pathway is present between the atria and the ventricles. Electrical impulses are rapidly conducted to the ventricles.
- These rapid impulses slur the initial portion of the QRS; the slurred effect is called a delta wave.



46

Rate: Depends on rate of underlying rhythm

Rhythm: Regular unless associated with A-fib

P Waves: Normal (upright and uniform) unless A-fib is present

PR Interval: Short (<0.12 sec) if P wave is present

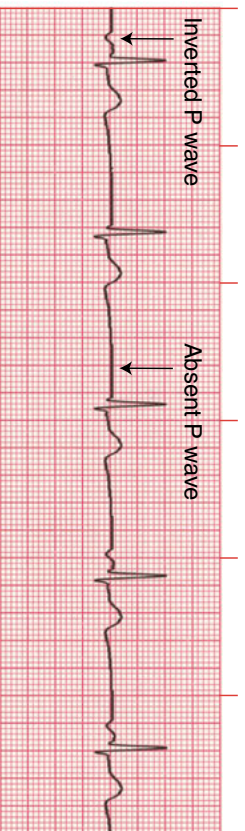
QRS: Wide (>0.10 sec); delta wave present

♥ **Clinical Tip:** WPW is associated with narrow-complex tachycardias, including A-flutter and A-fib.

Junctional Arrhythmias

- The atria and SA node do not perform their normal pacemaking functions.
- A junctional escape rhythm begins.

Junctional Rhythm



47

Rate: 40–60 bpm

Rhythm: Regular

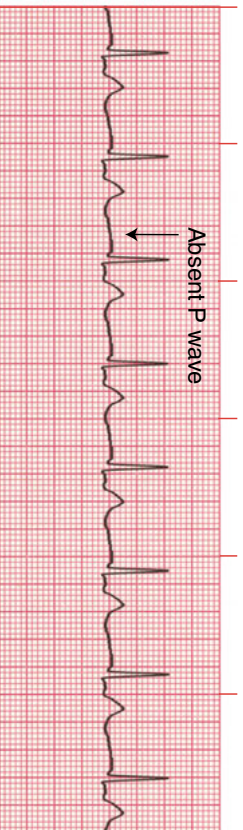
P Waves: Absent, inverted, buried, or retrograde

PR Interval: None, short, or retrograde

QRS: Normal (0.06–0.10 sec)

♥ **Clinical Tip:** Sinus node disease that causes inappropriate slowing of the sinus node may exacerbate this rhythm. Young, healthy adults, especially those with increased vagal tone during sleep, often have periods of junctional rhythm that is completely benign, not requiring intervention.

Accelerated Junctional Rhythm



Rate: 61–100 bpm

Rhythm: Regular

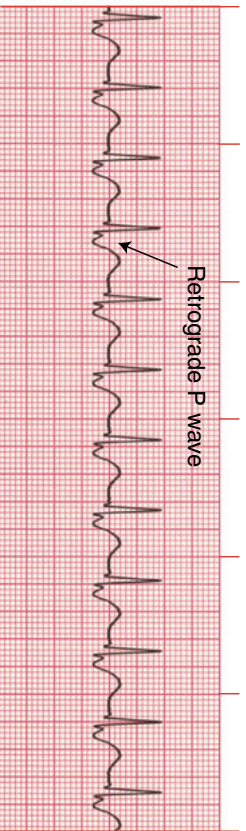
P Waves: Absent, inverted, buried, or retrograde

PR Interval: None, short, or retrograde

QRS: Normal (0.06–0.10 sec)

♥ **Clinical Tip:** Monitor the patient, not just the ECG, for clinical improvement.

Junctional Tachycardia



49

Rate: 101–180 bpm

Rhythm: Regular

P Waves: Absent, inverted, buried, or retrograde

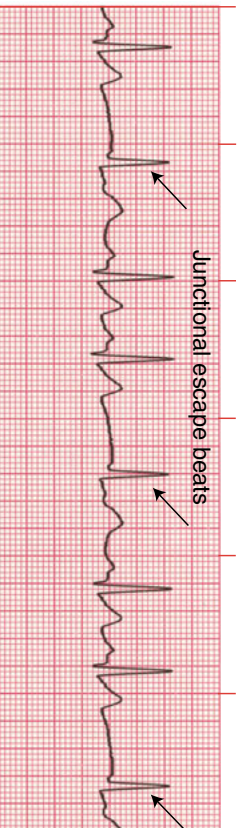
PR Interval: None, short, or retrograde

QRS: Normal (0.06–0.10 sec)

♥ **Clinical Tip:** Signs and symptoms of decreased cardiac output may be seen in response to the rapid rate.

Junctional Escape Beat

- An escape complex comes later than the next expected sinus complex.



Rate: Depends on rate of underlying rhythm

Rhythm: Irregular whenever an escape beat occurs

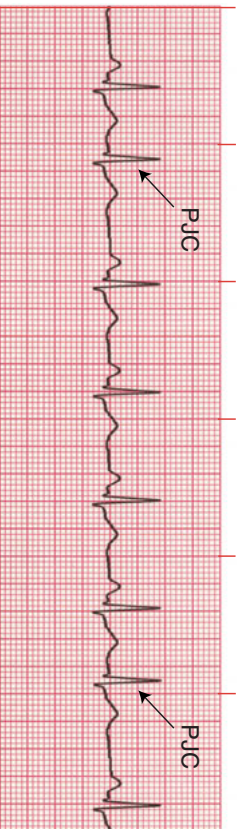P Waves: None, inverted, buried, or retrograde in the escape beat

PR Interval: None, short, or retrograde

QRS: Normal (0.06–0.10 sec)

Premature Junctional Contraction (PJC)

- Enhanced automaticity in the AV junction produces PJCs.



51

Rate: Depends on rate of underlying rhythm

Rhythm: Irregular whenever a PJC occurs

P Waves: Absent, inverted, buried, or retrograde in the PJC

PR Interval: None, short, or retrograde

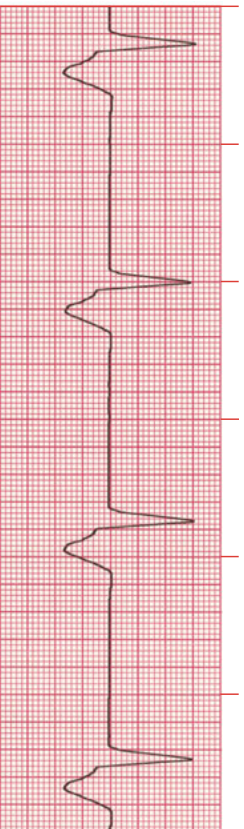
QRS: Normal (0.06–0.10 sec)

♥ **Clinical Tip:** Before deciding whether isolated PJCs are insignificant, consider the cause.

Ventricular Arrhythmias

- In all ventricular rhythms, the QRS complex is >0.10 sec. P Waves are absent or, if visible, have no consistent relationship to the QRS complex.

Idioventricular Rhythm



52

ECGS

Rate: 20–40 bpm

Rhythm: Regular

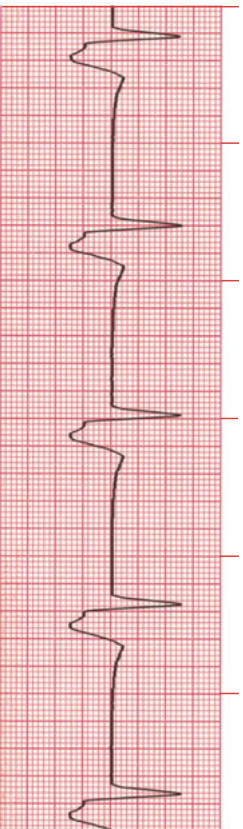
P Waves: None

PR Interval: None

QRS: Wide (>0.10 sec), bizarre appearance

♥ **Clinical Tip:** Diminished cardiac output is expected because of the slow heart rate. An idioventricular rhythm may be called an agonal rhythm when the heart rate drops below 20 bpm. An agonal rhythm is generally terminal and is usually the last rhythm before asystole.

Accelerated Idioventricular Rhythm



53

Rate: 41–100 bpm

Rhythm: Regular

P Waves: None

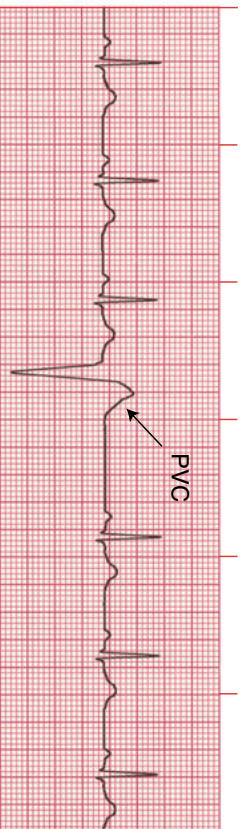
PR Interval: None

QRS: Wide (>0.10 sec), bizarre appearance

♥ **Clinical Tip:** Idioventricular rhythms appear when supraventricular pacing sites are depressed or absent. Diminished cardiac output is expected if the heart rate is slow.

Premature Ventricular Contraction (PVC)

- PVCs result from an irritable ventricular focus.
- PVCs may be uniform (same form) or multiform (different forms).
- Usually a PVC is followed by a full compensatory pause because the sinus node timing is not interrupted. In contrast, a PVC may be followed by a noncompensatory pause if the PVC enters the sinus node and resets its timing, enabling the following sinus P wave to appear earlier than expected.



Rate: Depends on rate of underlying rhythm

Rhythm: Irregular whenever a PVC occurs

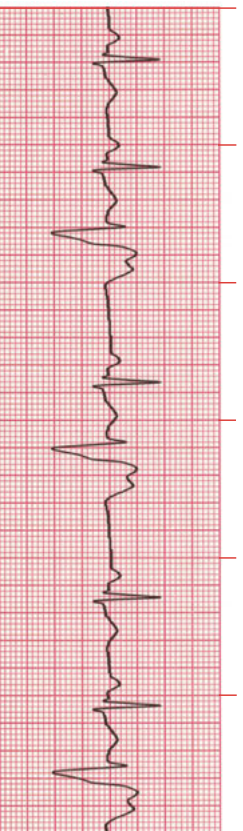
P Waves: None associated with the PVC

PR Interval: None associated with the PVC

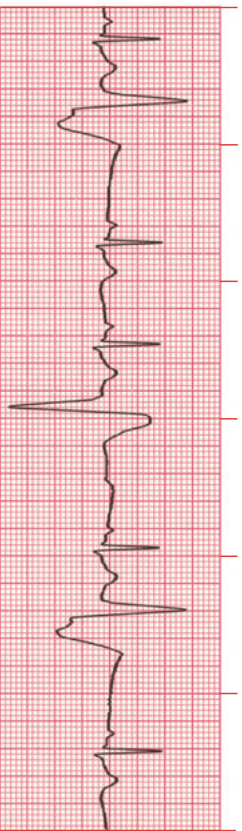QRS: Wide (>0.10 sec), bizarre appearance

♥ **Clinical Tip:** Patients may sense PVCs as skipped beats. Because the ventricles are only partially filled, the PVC frequently does not generate a pulse.

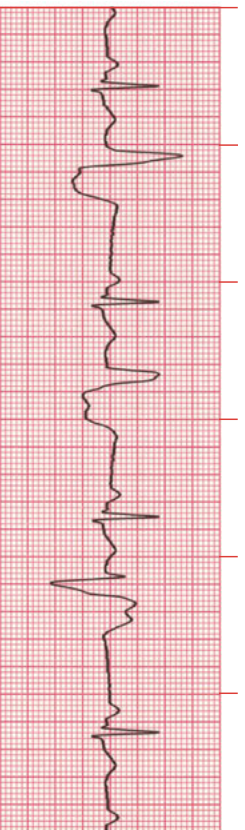
Premature Ventricular Contraction: Uniform (same form)



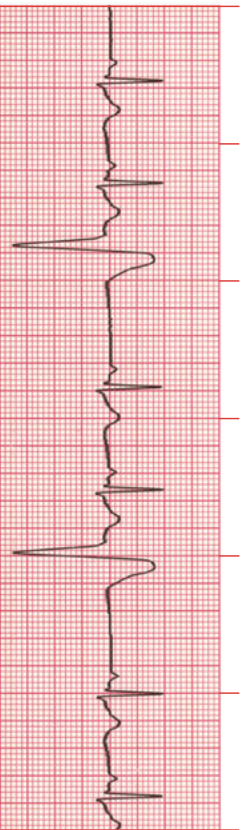
59 Premature Ventricular Contraction: Multiform (different forms)



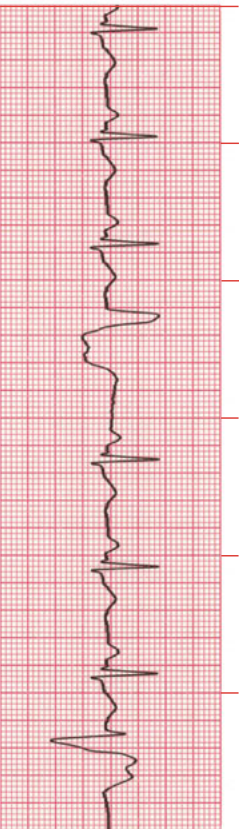
Premature Ventricular Contraction: Ventricular Bigeminy (PVC every 2nd beat)



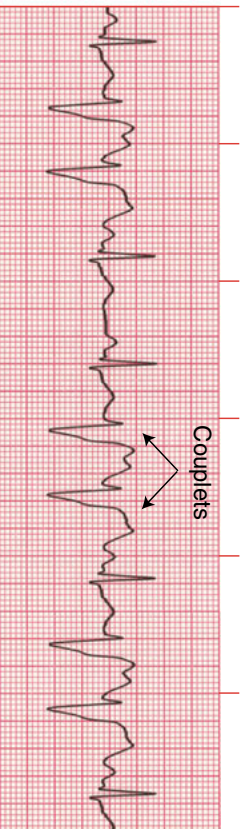
Premature Ventricular Contraction: Ventricular Trigeminy (PVC every 3rd beat)



Premature Ventricular Contraction: Ventricular Quadrigeminy (PVC every 4th beat)

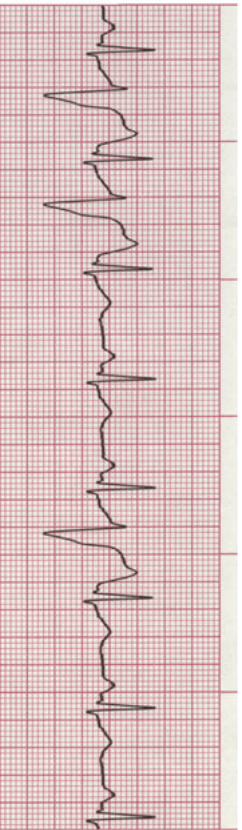


57 Premature Ventricular Contraction: Couplets (paired PVCs)



Premature Ventricular Contraction: R-on-T Phenomenon

- The PVCs occur so early that they fall on the T wave of the preceding beat.
- These PVCs occur during the refractory period of the ventricles, a vulnerable period because the cardiac cells have not fully repolarized.



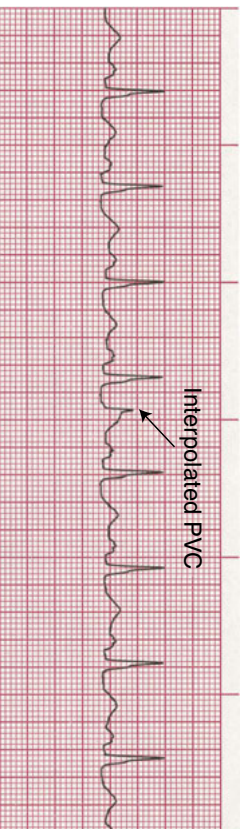
58

- Rate:** Depends on rate of underlying rhythm
- Rhythm:** Irregular whenever a PVC occurs
- P Waves:** None associated with the PVC
- PR Interval:** None associated with the PVC
- QRS:** Wide (>0.10 sec), bizarre appearance

♥ **Clinical Tip:** In acute ischemia, R-on-T phenomenon may be especially dangerous because the ventricles may be more vulnerable to ventricular tachycardia (VT) or ventricular fibrillation (VF).

Premature Contraction: Interpolated PVC

- The PVC occurs between two regular complexes; it may appear sandwiched between two normal beats.
- An interpolated PVC does not interfere with the normal cardiac cycle.

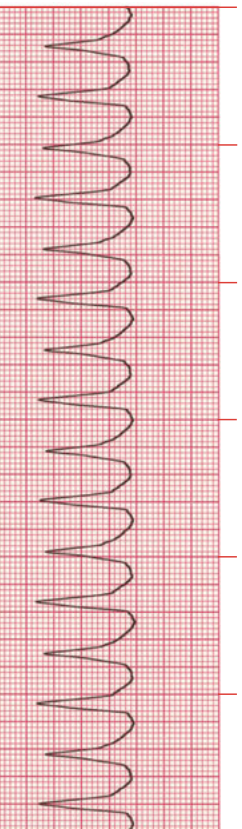


59

- Rate:** Depends on rate of underlying rhythm
- Rhythm:** Irregular whenever a PVC occurs
- P Waves:** None associated with the PVC
- PR Interval:** None associated with the PVC
- QRS:** Wide (>0.10 sec), bizarre appearance

Ventricular Tachycardia (VT): Monomorphic

- In monomorphic VT, QRS complexes have the same shape and amplitude.



60

Rate: 100–250 bpm

Rhythm: Regular

P Waves: None or not associated with the QRS

PR Interval: None

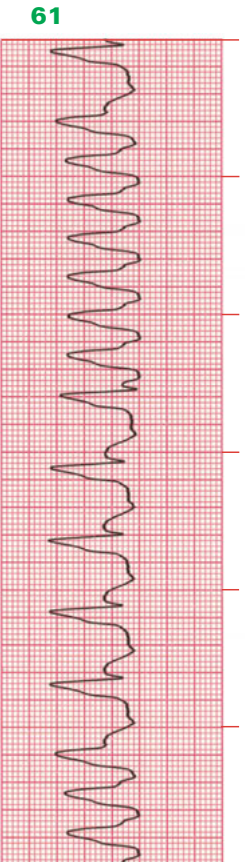
QRS: Wide (>0.10 sec), bizarre appearance

♥ **Clinical Tip:** It is important to confirm the presence or absence of pulses because monomorphic VT may be perfusing or nonperfusing.

♥ **Clinical Tip:** Monomorphic VT will probably deteriorate into VF or unstable VT if sustained and not treated.

Ventricular Tachycardia (VT): Polymorphic

- In polymorphic VT, QRS complexes vary in shape and amplitude.
- The QT interval is normal or long.



Rate: 100–250 bpm

Rhythm: Regular or irregular

P Waves: None or not associated with the QRS

PR Interval: None

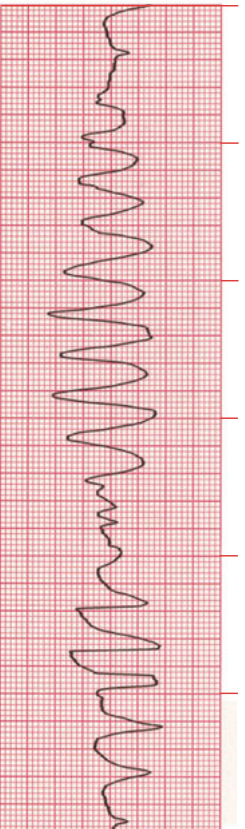
QRS: Wide (>0.10 sec), bizarre appearance

♥ **Clinical Tip:** It is important to determine whether pulses are present because polymorphic VT may be perfusing or nonperfusing.

♥ **Clinical Tip:** Consider electrolyte abnormalities as a possible cause.

Torsade de Pointes

- The QRS reverses polarity and the strip shows a spindle effect.
- This rhythm is an unusual variant of polymorphic VT with long QT intervals.
- In French the term means “twisting of points.”



62

ECGs

Rate: 200–250 bpm

Rhythm: Irregular

P Waves: None

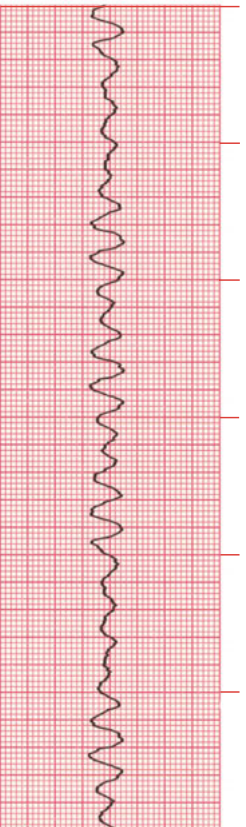
PR Interval: None

QRS: Wide (>0.10 sec), bizarre appearance

- ♥ **Clinical Tip:** Torsade de pointes may deteriorate to VF or asystole.
- ♥ **Clinical Tip:** Frequent causes are drugs that prolong the QT interval, and electrolyte abnormalities such as hypomagnesemia.

Ventricular Fibrillation (VF)

- Chaotic electrical activity occurs with no ventricular depolarization or contraction.
- The amplitude and frequency of the fibrillatory activity can define the type of fibrillation as coarse, medium, or fine. Small baseline undulations are considered fine; large ones are coarse.



Rate: Indeterminate

Rhythm: Chaotic

P Waves: None

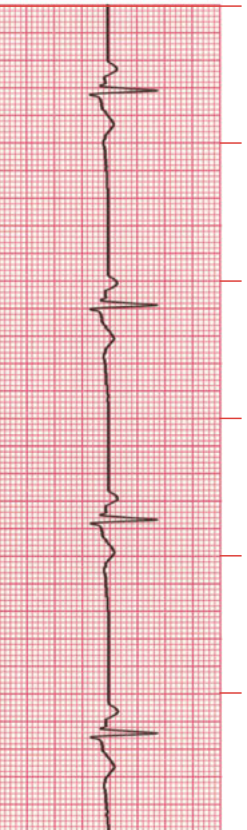
PR Interval: None

QRS: None

♥ **Clinical Tip:** There is no pulse or cardiac output. Rapid intervention is critical. The longer the delay, the less the chance of conversion.

Pulseless Electrical Activity (PEA)

- The monitor shows an identifiable electrical rhythm, but no pulse is detected.
- The rhythm may be sinus, atrial, junctional, or ventricular.
- PEA is also called electromechanical dissociation (EMD).




64

- **Rate:** Reflects underlying rhythm
- **Rhythm:** Reflects underlying rhythm
- **P Waves:** Reflects underlying rhythm
- **PR Interval:** Reflects underlying rhythm
- **QRS:** Reflects underlying rhythm

♥ **Clinical Tip:** Potential causes of PEA are trauma, tension pneumothorax, thrombosis (pulmonary or coronary), cardiac tamponade, toxins, hypo- or hyperkalemia, hypovolemia, hypoxia, hypoglycemia, hypothermia, and hydrogen ion (acidosis).

Asystole

- Electrical activity in the ventricles is completely absent.



Rate: None

Rhythm: None

P Waves: None

PR Interval: None

QRS: None

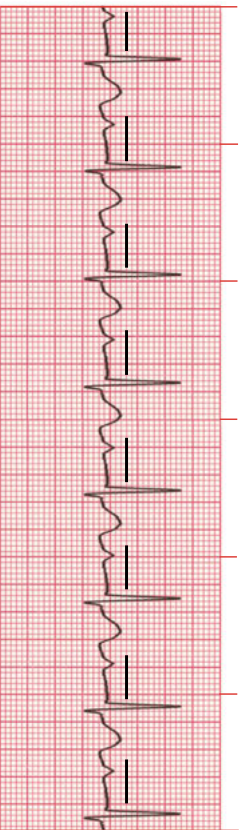
♥ **Clinical Tip:** Rule out other causes such as loose leads, no power, or insufficient signal gain.

♥ **Clinical Tip:** Seek to identify the underlying cause as in PEA. Also, search to identify VF.

Atrioventricular (AV) Blocks

- AV blocks are divided into three categories: first, second, and third degree.

First-Degree AV Block



Rate: Depends on rate of underlying rhythm

Rhythm: Regular

P Waves: Normal (upright and uniform)

PR Interval: Prolonged (>0.20 sec)

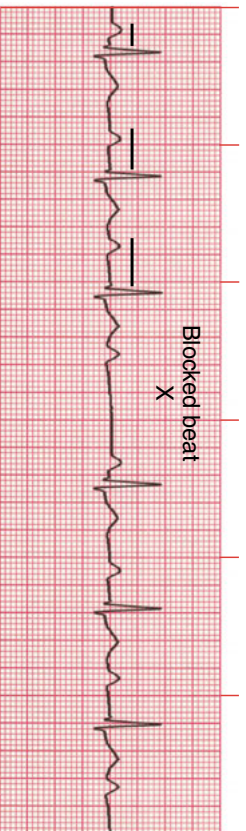
QRS: Normal (0.06–0.10 sec)

♥ **Clinical Tip:** Usually a first-degree AV block is benign, but if associated with an acute MI it may lead to further AV defects.

♥ **Clinical Tip:** Often AV block is caused by medications that prolong AV conduction; these include digoxin, calcium channel blockers, and beta blockers.

Second-Degree AV Block—Type I (Mobitz I or Wenckebach)

- PR intervals become progressively longer until one P wave is totally blocked and produces no QRS complex. After a pause, during which the AV node recovers, this cycle is repeated.



67

Rate: Depends on rate of underlying rhythm

Rhythm: Atrial: regular; ventricular: irregular

P Waves: Normal (upright and uniform), more P waves than QRS complexes

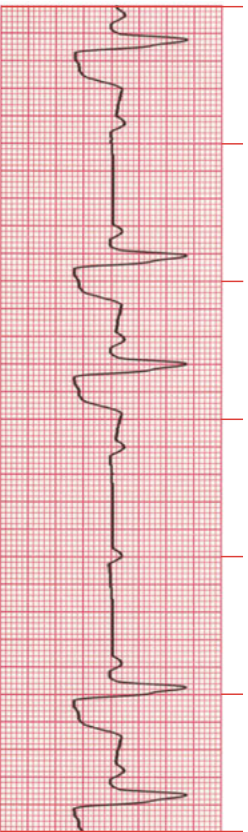
PR Interval: Progressively longer until one P wave is blocked and a QRS is dropped

QRS: Normal (0.06–0.10 sec)

♥ **Clinical Tip:** This rhythm may be caused by medication such as beta blockers, digoxin, and calcium channel blockers. Ischemia involving the right coronary artery is another cause.

Second-Degree AV Block—Type II (Mobitz II)

- Conduction ratio (P waves to QRS complexes) is commonly 2:1, 3:1, or 4:1, or variable.
- QRS complexes are usually wide because this block usually involves both bundle branches.



Rate: Atrial: usually 60–100 bpm; ventricular: slower than atrial rate

Rhythm: Atrial: regular; ventricular: regular or irregular

P Waves: Normal (upright and uniform); more P waves than QRS complexes

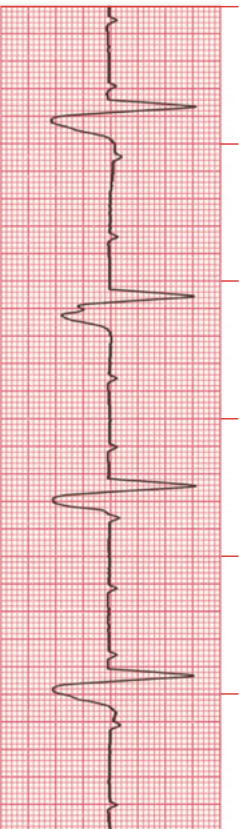
PR Interval: Normal or prolonged but constant

QRS: May be normal, but usually wide (>0.10 sec) if the bundle branches are involved

♥ **Clinical Tip:** Resulting bradycardia can compromise cardiac output and lead to complete AV block. This rhythm often occurs with cardiac ischemia or an MI.

Third-Degree AV Block

- Conduction between atria and ventricles is totally absent because of complete electrical block at or below the AV node. This is known as AV dissociation.
- “Complete heart block” is another name for this rhythm.



69

Rate: Atrial: 60–100 bpm; ventricular: 40–60 bpm if escape focus is junctional, <40 bpm if escape focus is ventricular

Rhythm: Usually regular, but atria and ventricles act independently

P Waves: Normal (upright and uniform); may be superimposed on QRS complexes or T waves

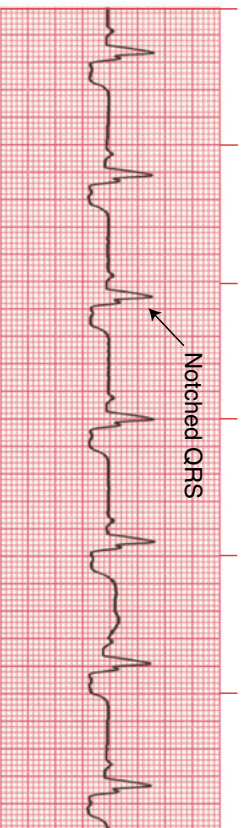
PR Interval: Varies greatly

QRS: Normal if ventricles are activated by junctional escape focus; wide if escape focus is ventricular

♥ **Clinical Tip:** Third-degree AV block may be associated with ischemia involving the left coronary arteries.

Bundle Branch Block (BBB)

- Either the left or the right ventricle may depolarize late, creating a “wide” or “notched” QRS complex.



70

Rate: Depends on rate of underlying rhythm

Rhythm: Regular

P Waves: Normal (upright and uniform)

PR Interval: Normal (0.12–0.20 sec)

QRS: Wide (>0.10 sec) with a notched appearance

♥ **Clinical Tip:** Bundle branch block commonly occurs in coronary artery disease.

Artificial Cardiac Pacemakers

- Artificial pacemakers electronically stimulate the heart in place of the heart's own pacemaker.
- Pacemakers may be preset to stimulate the heart's activity continuously or intermittently.

Temporary Pacemaker

- Paces the heart through epicardial, transvenous, or transcutaneous routes. The pulse generator is located externally.

Permanent Pacemaker

- Its circuitry sealed in an airtight case, the pacemaker is implanted in the body. It uses sensing and pacing device leads.

Single-Chamber Pacemaker

- One lead is placed in the heart and paces a single heart chamber (either atrium or ventricle).

Dual-Chamber Pacemaker

- One lead is placed in the right atrium and the other in the right ventricle. The atrial electrode generates a spike that should be followed by a P wave, and the ventricular electrode generates a spike followed by a wide QRS complex.

Pacemaker Modes

- Fixed rate (asynchronous): Discharges at a preset rate (usually 70–80 bpm) regardless of the patient's own electrical activity.
- Demand (synchronous): Discharges only when the patient's heart rate drops below the pacemaker's preset (base) rate.

♥ **Clinical Tip:** Patients with pacemakers may receive defibrillation, but avoid placing the defibrillator paddles or pads closer than 5 inches to the pacemaker battery pack.

Artificial Cardiac Pacemakers

Pacemaker Codes

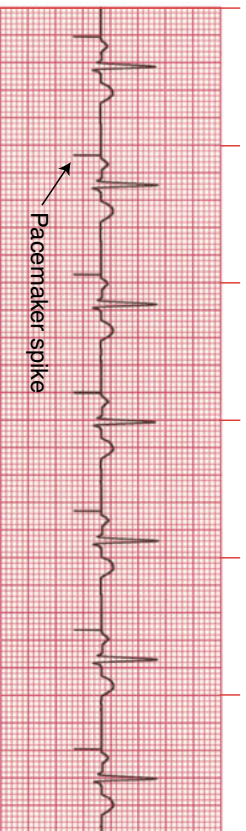
Chamber Paced	Chamber Sensed	Response to Sensing	Programmable Functions	Response to Tachycardia
A = Atrium V = Ventricle D = Dual (atrium and ventricle) O = None	A = Atrium V = Ventricle D = Dual (atrium and ventricle) O = None	T = Triggers pacing I = Inhibits pacing D = Dual (triggers and inhibits) O = None	P = Basic programs (rate and output) M = Multiple programs C = Communication (i.e., telemetry) R = Rate response O = None	P = Pacing S = Shock D = Dual (pace and shock) O = None

Artificial Pacemaker Rhythm

Rate	Varies according to preset pacemaker rate.
Rhythm	Regular for asynchronous pacemaker; irregular for demand pacemaker unless 100% paced with no intrinsic beats.
P waves	None produced by ventricular pacemaker. Sinus P waves may be seen but are unrelated to QRS. Atrial or dual-chamber pacemaker should have P waves following each atrial spike.
PR Interval	None for ventricular pacer. Atrial or dual-chamber pacemaker produces constant PR intervals.
QRS	Wide (>0.10 sec) following each ventricular spike in a pacemaker rhythm. The patient's own electrical activity may generate a QRS complex that looks different from the paced QRSs. If atrially paced only, the QRS may be within normal limits.

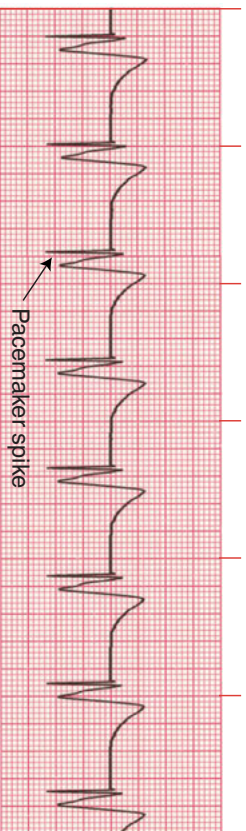
- ♥ **Clinical Tip:** Once an impulse is generated by the pacemaker, it appears as a spike, either above or below the baseline (isoelectric line), on the ECG. The spike indicates that the pacemaker has fired.
- ♥ **Clinical Tip:** A pacemaker is in capture when a spike produces an ECG wave or complex.

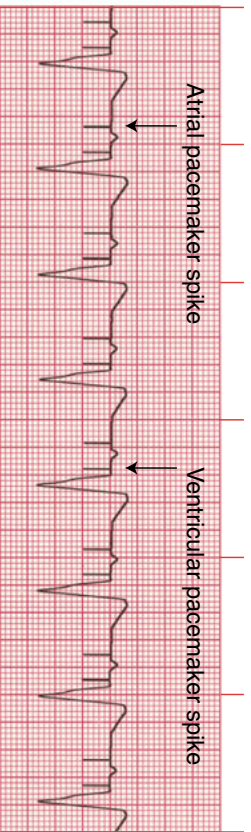
Single-Chamber Pacemaker Rhythm—Atrial



73

Single-Chamber Pacemaker Rhythm—Ventricular



Dual-Chamber Pacemaker Rhythm—Atrial and Ventricular

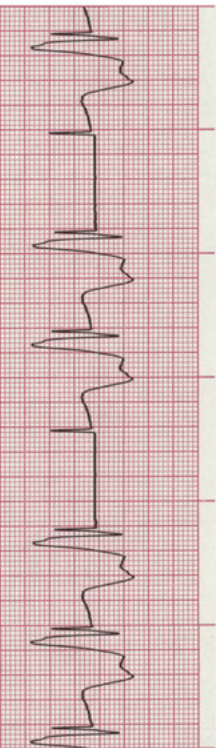
Notes:

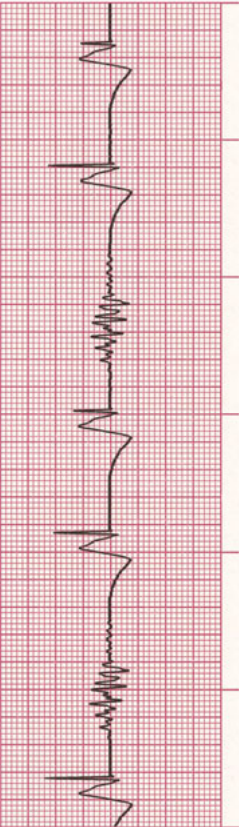
Pacemaker Malfunctions

Malfunction	Reason
Failure to pace	Pacemaker spikes are absent. The cause may be a dead battery, a disruption in the connecting wires, or improper programming.
Failure to capture	Pacemaker spikes are present, but no P wave or QRS follows the spike. Turning up the pacemaker's voltage often corrects this problem. Lead wires should also be checked—a dislodged or broken lead wire may not deliver the needed energy.
Failure to sense	The pacemaker fires because it fails to detect the heart's intrinsic beats, resulting in abnormal complexes. The cause may be a dead battery, decrease of P wave or QRS voltage, or damage to a pacing lead wire. One serious potential consequence may be an R-on-T phenomenon.
Oversensing	The pacemaker may be too sensitive and misinterpret muscle movement or other events in the cardiac cycle as depolarization. This error resets the pacemaker inappropriately, increasing the amount of time before the next discharge.

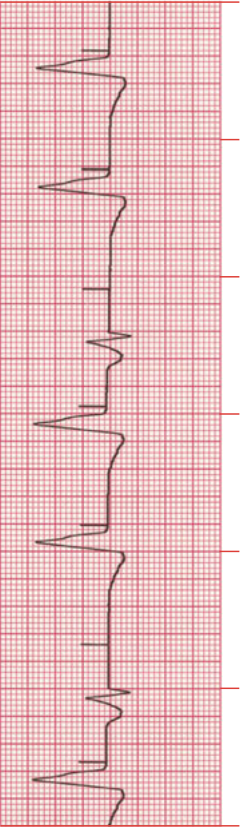
75

Pacemaker Failure to Capture





Pacemaker Oversensing

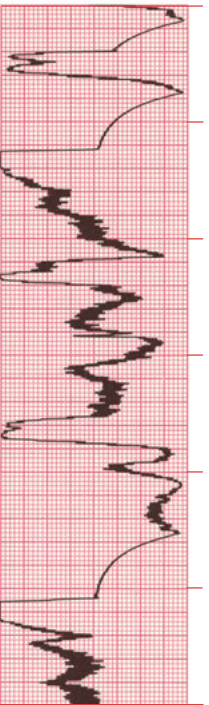


Pacemaker Failure to Sense

Artifact

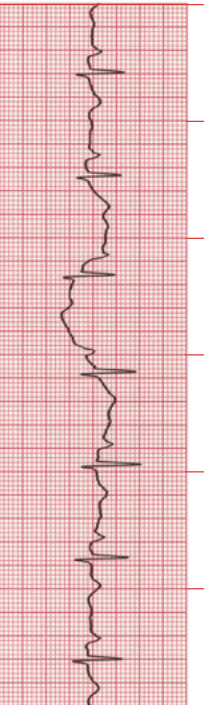- Artifacts are ECG deflections caused by influences other than the heart's electrical activity.

Loose Electrodes

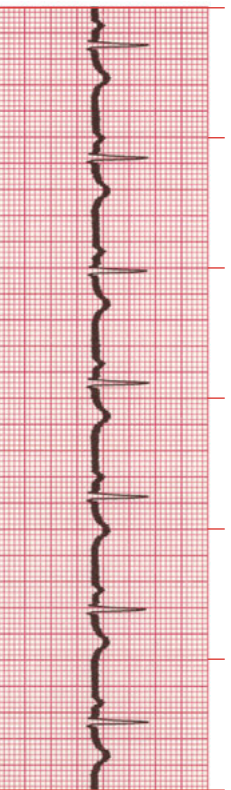


77

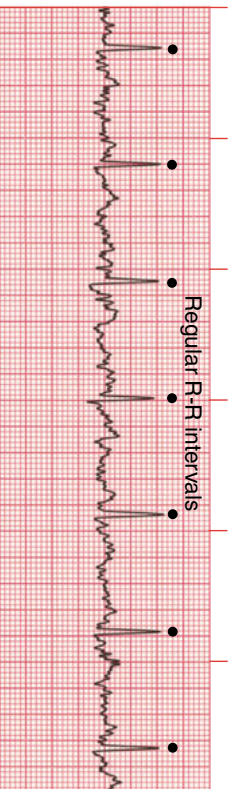Baseline Varies With Respiration



60-Cycle Interference



Muscle Artifact



♥ **Clinical Tip:** Never confuse muscle artifact with A-fib if the rhythm is regular.

The 12-Lead ECG

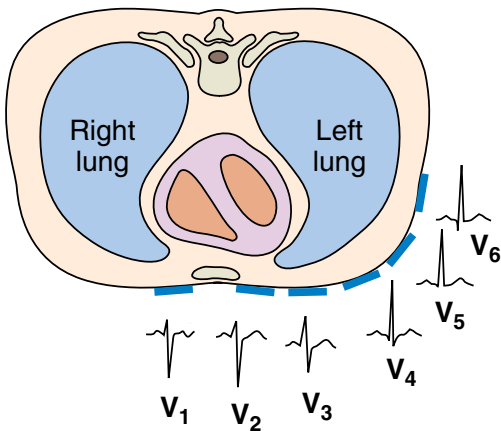
A standard 12-lead ECG provides views of the heart from 12 different angles. This diagnostic test helps to identify pathological conditions, especially bundle branch blocks and T wave changes associated with ischemia, injury, and infarction. The 12-lead ECG also uses ST segment analysis to pinpoint the specific location of an MI.

The 12-lead ECG is the type most commonly used in clinical settings. The following list highlights some of its important aspects:

- The 12-lead ECG consists of the six limb leads—I, II, III, aVR, aVL, and aVF—and the six chest leads—V₁, V₂, V₃, V₄, V₅, and V₆.
- The limb leads record electrical activity in the heart's frontal plane. This view shows the middle of the heart from top to bottom. Electrical activity is recorded from the anterior-to-posterior axis.
- The chest leads record electrical activity in the heart's horizontal plane. This transverse view shows the middle of the heart from left to right, dividing it into upper and lower portions. Electrical activity is recorded from either a superior or an inferior approach.
- Measurements are central to 12-lead ECG analysis. The height and depth of waves can offer important diagnostic information in certain conditions, including MI and ventricular hypertrophy.
- The direction of ventricular depolarization is an important factor in determining the axis of the heart.
- In an MI, multiple leads are necessary to recognize its presence and determine its location. If large areas of the heart are affected, the patient can develop cardiogenic shock and fatal arrhythmias.
- ECG signs of an MI are best seen in the reciprocal, or reflecting, leads—those facing the affected surface of the heart. Reciprocal leads are in the same plane but opposite the area of infarction; they show a "mirror image" of the electrical complex.
- Prehospital EMS systems may use 12-lead ECGs to discover signs of acute MI, such as ST segment elevation, in preparation for in-hospital administration of thrombolytic drugs.
- After a 12-lead ECG is performed, a 15-lead, or right-sided, ECG may be used for an even more comprehensive view if the right ventricle or the posterior portion of the heart appears to be affected.

R Wave Progression

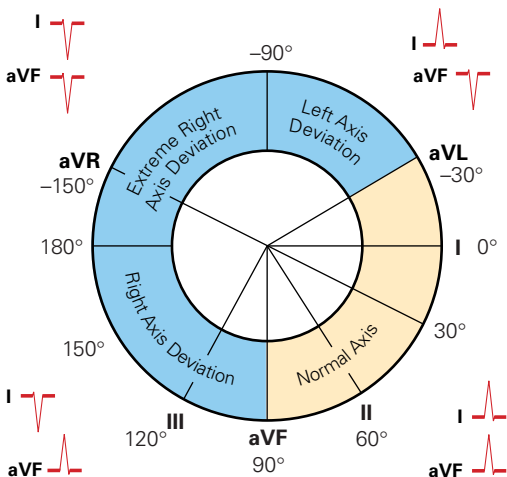
- Normal ventricular depolarization in the heart progresses from right to left and from front to back.
- In a normal heart, the R wave becomes taller and the S wave smaller as electrical activity crosses the heart from right to left. This phenomenon is called R wave progression and is noted on the chest leads.
- Alteration in the normal R wave progression may be seen in left ventricular hypertrophy, COPD, left bundle branch block, or anteroseptal MI.



Normal R wave progression in chest leads V₁-V₆

Electrical Axis Deviation

- The electrical axis is the sum total of all electrical currents generated by the ventricular myocardium during depolarization.
- Analysis of the axis may help to determine the location and extent of cardiac injury, such as ventricular hypertrophy, bundle branch block, or changes in the position of the heart in the chest (e.g., from pregnancy or ascites).
- The direction of the QRS complex in leads I and aVF determines the axis quadrant in relation to the heart.

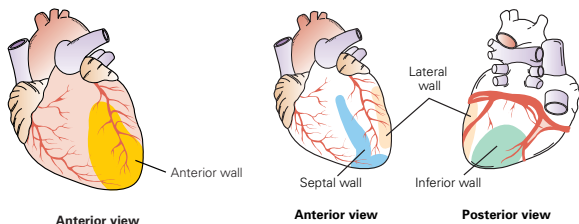


Electrical axis of the heart.

♥ **Clinical Tip:** Extreme right axis deviation is also called indeterminate, "no man's land," and "northwest."

Ischemia, Injury, and Infarction in Relation to the Heart

Ischemia, injury, and infarction of cardiac tissue are the three stages resulting from complete blockage in a coronary artery. The location of the MI is critical in determining the most appropriate treatment and predicting probable complications. Each coronary artery delivers blood to specific areas of the heart. Blockages at different sites can damage various parts of the heart. Characteristic ECG changes occur in different leads with each type of MI and can be correlated to the blockages.



Location of MI by ECG Leads

I lateral	aVR	V ₁ septal	V ₄ anterior
II inferior	aVL lateral	V ₂ septal	V ₅ lateral
III inferior	aVF inferior	V ₃ anterior	V ₆ lateral

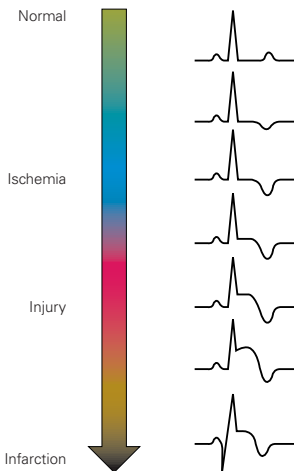
♥ **Clinical Tip:** Lead aVR may not show any change in an MI.

♥ **Clinical Tip:** An MI may not be limited to just one region of the heart. For example, if there are changes in leads V₃ and V₄ (anterior) and leads I, aVL, V₅, and V₆ (lateral), the MI is called an anterolateral infarction.

Progression of an Acute Myocardial Infarction

An acute MI is a continuum that extends from the normal state to a full infarction:

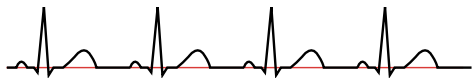
- Ischemia—Lack of oxygen to the cardiac tissue, represented by ST segment depression, T wave inversion, or both
- Injury—Arterial occlusion with ischemia, represented by ST segment elevation
- Infarction—Death of tissue, represented by a pathological Q wave




♥ **Clinical Tip:** Once the acute MI has ended, the ST segment returns to baseline and the T wave becomes upright, but the Q wave remains abnormal because of scar formation.

ST Segment Elevation and Depression

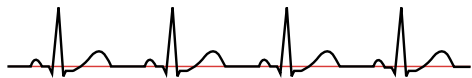
- A normal ST segment represents early ventricular repolarization.
- Displacement of the ST segment can be caused by the following various conditions



ST segment is at baseline.



ST segment is elevated.



ST segment is depressed.

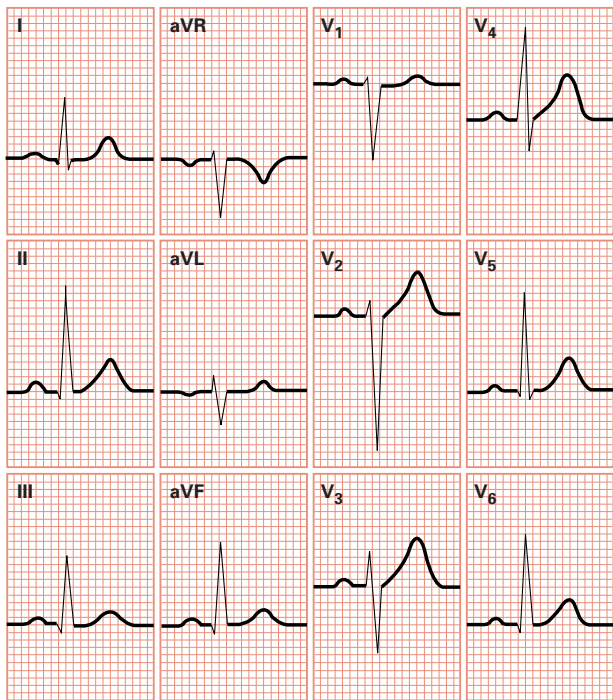
Primary Causes of ST Segment Elevation

- ST segment elevation exceeding 1 mm in the limb leads and 2 mm in the chest leads indicates an evolving acute MI until there is proof to the contrary. Other primary causes of ST segment elevation are:
 - Early repolarization (normal variant in young adults)
 - Pericarditis, ventricular aneurysm
 - Pulmonary embolism, intracranial hemorrhage

Primary Causes of ST Segment Depression

- Myocardial ischemia, left ventricular hypertrophy
- Intraventricular conduction defects
- Medication (e.g., digitalis)
- Reciprocal changes in leads opposite the area of acute injury

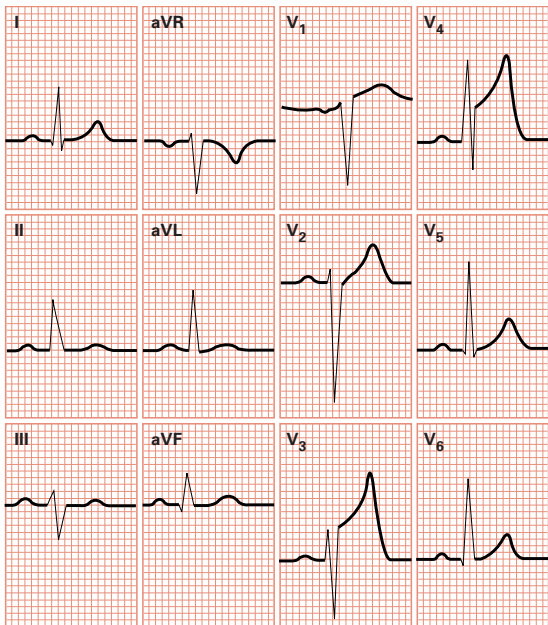
The Normal 12-Lead ECG



♥ **Clinical Tip:** A normal ECG does not rule out any acute coronary syndrome.

Anterior Myocardial Infarction

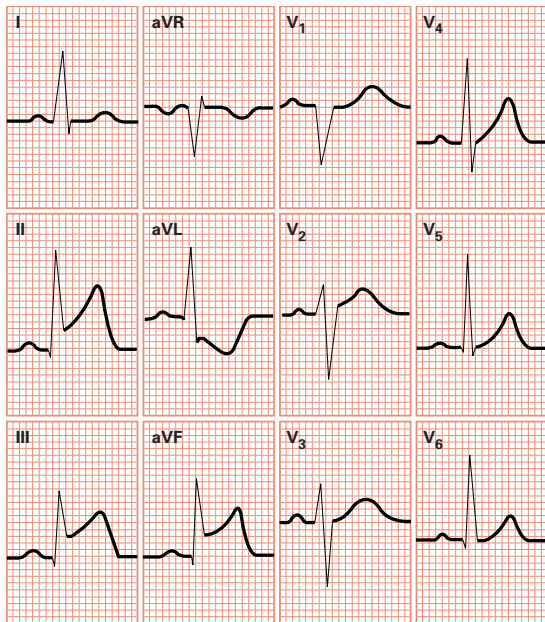
- Occlusion of the left coronary artery—left anterior descending branch
- ECG changes: ST segment elevation with tall T waves and taller-than-normal R waves in leads V_3 and V_4 ; reciprocal changes in II, III, and aVF



♥ **Clinical Tip:** Anterior MI frequently involves a large area of the myocardium and can present with cardiogenic shock, second-degree AV block type II, or third-degree AV block.

Inferior Myocardial Infarction

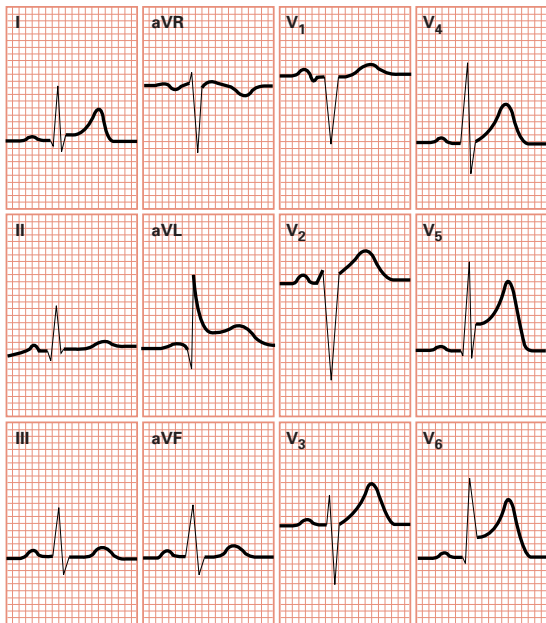
- Occlusion of the right coronary artery—posterior descending branch
- ECG changes: ST segment elevation in leads II, III, and aVF; reciprocal ST segment depression in I and aVL



♥ **Clinical Tip:** Be alert for symptomatic sinus bradycardia, AV blocks, hypotension, and hypoperfusion.

Lateral Myocardial Infarction

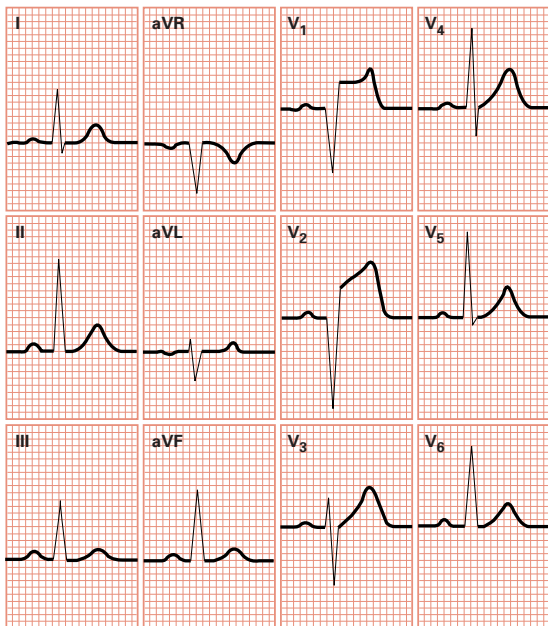
- Occlusion of the left coronary artery—circumflex branch
- ECG changes: ST segment elevation in leads I, aVL, V₅, and V₆; reciprocal ST segment depression in V₁, V₂, and V₃



♥ **Clinical Tip:** Lateral MI is often associated with anterior or inferior wall MI. Be alert for changes that may indicate cardiogenic shock or congestive heart failure.

Septal Myocardial Infarction

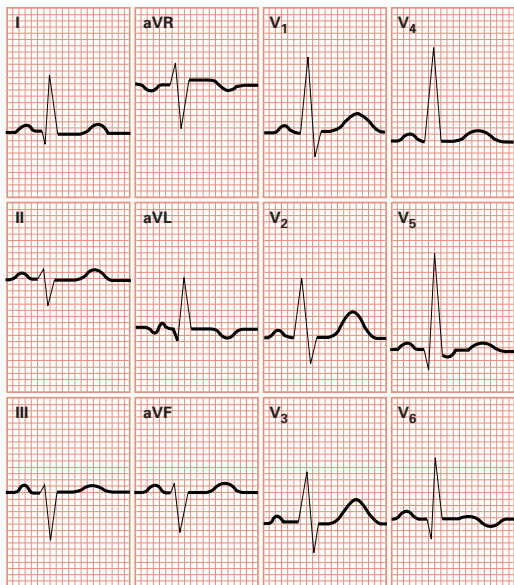
- Occlusion of the left coronary artery—left anterior descending branch
- ECG changes: pathological Q waves; absence of normal R waves in leads V_1 and V_2



♥ **Clinical Tip:** Septal MI is often associated with an anterior wall MI.

Posterior Myocardial Infarction

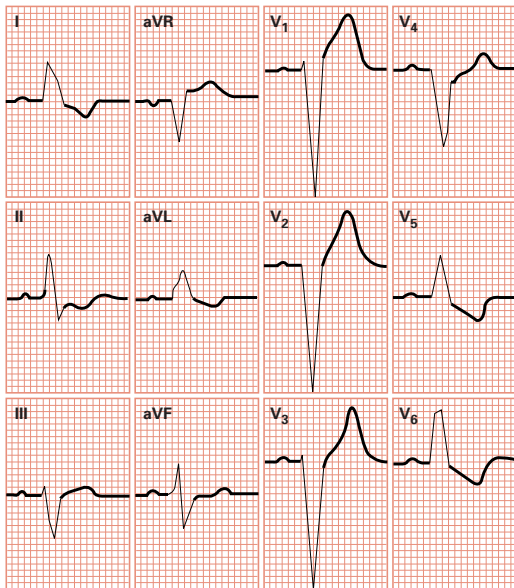
- Occlusion of the right coronary artery (posterior descending branch) or the left circumflex artery
- Usually, tall R waves and ST segment depression in leads V_1 , V_2 , V_3 , and V_4 ; possible left ventricular dysfunction
- You may need to view the true posterior leads, V_8 and V_9 (used in the 15-lead ECG), for definite diagnosis of an acute posterior MI. These leads show ST segment elevation



♥ **Clinical Tip:** Diagnosis may require a 15-lead ECG because a standard 12-lead does not look directly at the posterior wall.

Left Bundle Branch Block

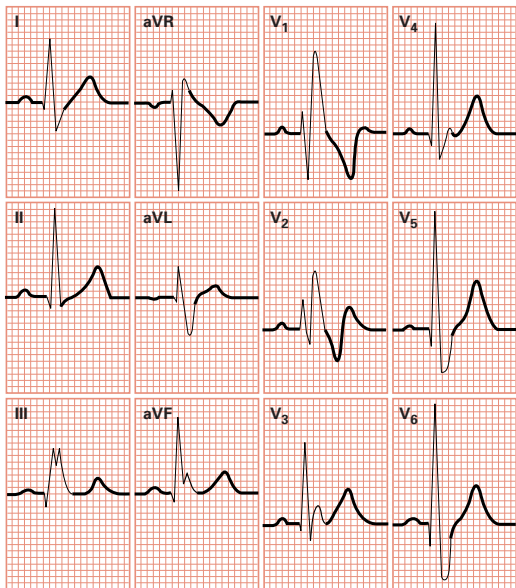
- QRS complex greater than 0.10 sec
- QRS predominantly negative in leads V_1 and V_2
- QRS predominantly positive in V_5 and V_6 and often notched
- Absence of small, normal Q waves in I, aVL, V_5 , and V_6
- Wide monophasic R waves in I, aVL, V_1 , V_5 , and V_6



♥ **Clinical Tip:** Patients may have underlying heart disease, including coronary artery disease, hypertension, cardiomyopathy, and ischemia.

Right Bundle Branch Block

- QRS complex greater than 0.10 sec
- QRS axis normal or deviated to the right
- Broad S wave in leads I, aVL, V₅, and V₆
- RSR' pattern in lead V₁ with R' taller than R
- qRS pattern in V₅ and V₆
- ST segment to T wave distorted and in opposite direction to terminal portion of QRS (this is not ST elevation or ST depression)



♥ Patients may have underlying right ventricular hypertrophy, pulmonary edema, cardiomyopathy, congenital heart disease, or rheumatic heart disease.

Emergency Medications

This is a reference list only. It is not meant to be exhaustive in clinical content. Drug dosages follow Advanced Cardiac Life Support (ACLS) guidelines for adult patients and Pediatric Advanced Life Support (PALS) guidelines for pediatric patients.

Always consult an authoritative, current reference about dose, dilution, route and rate of administration, and interactions before administering medications, especially IV medications. Have a second licensed person independently check dose calculations, preparation, original orders, and infusion pump programming.

ACE INHIBITORS (Angiotensin-Converting Enzyme Inhibitors)

Class: Antihypertensive.

Common Agents: Captopril, Enalapril, Lisinopril, Ramipril.

Indications: Myocardial infarction, hypertension (HTN), congestive heart failure (CHF), heart failure without hypotension, ST segment elevation, left ventricular dysfunction after MI.

Adult Dose: See individual order and drug for route and dosage.

Usually not started in the Emergency Department, but within 24 hr after reperfusion therapy has been completed and blood pressure (BP) has stabilized.

Contraindications: Lactation, pregnancy, angioedema, hypersensitivity to ACE inhibitors, serum potassium more than 5 mEq/L.

Side Effects: Cough, dizziness, headache, fatigue, hypotension, hyperkalemia, bronchospasm, angioedema.

Precautions: Reduce dose in renal failure.

ADENOSINE (Adenocard, Adenoscan)

Class: Antiarrhythmic

Indications: Regular narrow-complex tachycardias and PSVT.

Adult Dose: 6 mg IV in the antecubital or other large vein given rapidly over 1–3 sec followed by a 20-mL bolus of normal saline. Immediately elevate the arm. If the rhythm does not convert, give 12 mg by IV in 1–2 min if needed. A third dose of 12 mg IV may be given in another 1–2 min, maximum total dose 30 mg.

Pediatric Dose: 0.1 mg/kg IV/IO rapid push (maximum 6 mg), 2nd dose 0.2 mg/kg IV/IO rapid push (maximum 12 mg).

Contraindications: Hypersensitivity, sick sinus syndrome, second- or third-degree AV block (unless a functional artificial pacemaker is present), drug- or poison-induced tachycardia, asthma or other bronchospastic lung disease.

Side Effects: Flushing, dizziness, headache, dyspnea, bronchospasm, chest pain or tightness, discomfort in neck, throat, or jaw, bradycardia, AV block, asystole, ventricular ectopic beats, VF.

Precautions: Does not convert A-fib, A-flutter, or VT. Less effective (larger doses may be required) in patients taking theophylline or caffeine; reduce dose to 3 mg in patients receiving dipyridamole or carbamazepine.

AMIODARONE (Cordarone, Pacerone)

Class: Antiarrhythmic

Indications: Management of life-threatening recurrent VF or refractory hemodynamically unstable VT. Conversion of A-fib, SVT. Control of rapid ventricular rate in pre-excited atrial arrhythmias. Control of hemodynamically stable VT, polymorphic VT with normal QT interval, or wide-complex tachycardia of uncertain origin.

Adult Dose: *Cardiac arrest* 300 mg IV/IO (diluted in 20–30 mL D5W); consider additional 150 mg IV/IO in 3–5 min. *Wide- and narrow-complex tachycardia (stable)* 150 mg IV over first 10 min (15 mg/min)—may repeat infusion of 150 mg IV every 10 min as needed; slow infusion of 360 mg IV over next 6 hr (1 mg/min); maintenance infusion of 540 mg over next 18 hr (0.5 mg/min). Maximum cumulative dose 2.2 g IV in 24 hr.

Pediatric Dose: *Cardiac arrest* 5 mg/kg IV/IO bolus (maximum 300 mg), repeat to daily maximum 15 mg/kg (or 2.2 g). *Unstable SVT, VT (with pulses)* 5 mg/kg IV/IO load over 20 to 60 min (maximum 300 mg), repeat to daily maximum 15 mg/kg (or 2.2 g).

Contraindications: Hypersensitivity, cardiogenic shock, symptomatic bradycardia, or second- or third-degree AV block without functioning artificial pacemaker.

Side Effects: Vasodilation, bradycardia, hypotension, visual impairment, hepatotoxicity, pulmonary toxicity, CHF; may prolong QT interval producing torsade de pointes.

AMIODARONE *continued*

Precautions: Avoid concurrent use with procainamide. Correct hypokalemia and hypomagnesemia, if possible, before use. Draw up amiodarone through a large-gauge needle to reduce foaming. For slow or maintenance IV infusion, mix the medication only in a glass bottle containing D5W or normal saline and administer through an in-line filter. Terminal elimination is extremely long (half-life lasts up to 40 days).

ASPIRIN (Acetylsalicylic Acid)

Class: Antiplatelet

Indications: Acute coronary syndrome, symptoms suggestive of cardiac ischemia.

Adult Dose: 160–325 mg PO. Chewing the tablet is preferable; use non-enteric coated tablets for antiplatelet effect. Give within minutes of onset of ischemic symptoms.

Contraindications: Known allergy to aspirin, pregnancy.

Side Effects: Anorexia, nausea, epigastric pain, anaphylaxis.

Precautions: Active ulcers and asthma, bleeding disorders or thrombocytopenia.

ATROPINE SULFATE

Class: Antiarrhythmic, Anticholinergic

Indications: Symptomatic sinus bradycardia, junctional escape rhythm, second-degree type I AV block, asystole, bradycardic PEA (<60 bpm). Not likely to be effective in second-degree type II or third-degree AV block with wide QRS complex.

Adult Dose: *Cardiac arrest* 1 mg IV/IO every 3–5 min (may give through an endotracheal [ET] tube at 2.0–3.0 mg diluted in 10 mL normal saline). May repeat to a maximum of three doses (3 mg).

Symptomatic sinus bradycardia 0.5mg IV given every 3–5 min as needed, maximum total dose 3 mg (0.04 mg/kg).

Pediatric Dose: *Symptomatic sinus bradycardia* 0.02 mg/kg IV/IO (minimum dose 0.1 mg, maximum single dose child 0.5 mg, maximum single dose adolescent 1 mg), may repeat dose once, maximum total dose child 1 mg, maximum total dose adolescent 2 mg. Give 0.04–0.06 mg/kg diluted in 3–5 mL normal saline if administering by ET tube.

Contraindications: Atrial fibrillation, A-flutter, glaucoma, asthma, obstructive uropathy.

Side Effects: Tachycardia, headache, dry mouth, flushing, hypotension, dilated pupils.

Precautions: Use caution in myocardial ischemia and hypoxia. Avoid in hypothermic bradycardia and in second-degree (Mobitz type II) and third-degree AV block.

BETA BLOCKERS

Class: Antihypertensive, Antiarrhythmic, Antianginal

Common agents: Atenolol, Esmolol, Labetalol, Metoprolol tartrate, Propranolol.

Indications: Myocardial infarction, unstable angina, PSVT, A-fib, A-flutter, HTN.

Adult Dose: See individual order and drug for route and dosage.

Contraindications: Heart rate less than 50 or 60 bpm, systolic BP less than 100 mm Hg, second- or third-degree AV block, severe left ventricular failure.

Side Effects: Hypotension, dizziness, bradycardia, headache, nausea and vomiting.

Precautions: Concurrent use with calcium channel blockers, such as verapamil or diltiazem, can cause hypotension. Use caution in patients with a history of bronchospasm or cardiac failure. Use caution in patients with peripheral arterial disease and with diabetic patients (monitor blood glucose levels frequently).

CALCIUM CHLORIDE

Class: Minerals, Electrolytes, Calcium Salt

Indications: Hyperkalemia, hypocalcemia, hypermagnesemia; antidote to calcium channel blockers and beta blockers; given prophylactically with calcium channel blockers to prevent hypotension.

Adult Dose: *Hyperkalemia, hypocalcemia, hypermagnesemia, and antidote to calcium channel blocker overdose* 500–1000 mg IV (usually 5–10 mL of a 10% solution); may be repeated as needed. A 10% solution is 100 mg/mL in 10 mL.

Pediatric Dose: *Hyperkalemia, hypocalcemia, hypermagnesemia, and antidote to calcium channel blocker overdose* 20 mg/kg (0.2 mL/kg) IV of a 10% solution, slow push during arrest or, if severe hypotension, repeat as needed. A 10% solution is 100 mg/mL in 10 mL.

Contraindications: Hypercalcemia, VF, digoxin toxicity, renal calculi.

CALCIUM CHLORIDE *continued*

Side Effects: Bradycardia, hypotension, hypomagnesemia, VF, nausea and vomiting.

Precautions: Do not use routinely during resuscitation (may contribute to cellular injury); not recommended for routine treatment of asystole or PEA; rapid IV administration may cause hypotension, bradycardia, or asystole (particularly if patient is receiving digoxin); incompatible with sodium bicarbonate (precipitates).

DIGOXIN (Lanoxin)

Class: Inotropic, Antiarrhythmic

Indications: To slow ventricular response in A-fib or A-flutter, as a positive inotrope in CHF or pulmonary edema. May be used as an alternative drug for reentry SVT.

Adult Dose: Loading dose of 10–15 mcg/kg, administered IV over 5 min. Each 2-mL ampule contains 500 mcg (0.5 mg) digoxin (250 mcg [0.25mg] per mL). Maintenance dose determined by body size and renal function.

Contraindications: Hypersensitivity, uncontrolled ventricular arrhythmias, second- or third-degree AV block without functioning artificial pacemaker, idiopathic hypertrophic subaortic stenosis (IHSS), constrictive pericarditis, A-fib with WPW syndrome.

Side Effects: Accelerated junctional rhythm, atrial tachycardia with block, AV block, asystole, VT, VF; dizziness, weakness, fatigue; nausea and vomiting, diarrhea; blurred or yellow vision; headache; hypersensitivity.

Precautions: Avoid electrical cardioversion of stable patients. If the patient's condition is unstable, use lower current settings such as 10–20 J. Use cautiously in elderly patients. Correct electrolyte abnormalities, monitor digoxin levels, monitor for clinical signs of toxicity. Hypokalemia may precipitate digitalis toxicity. Avoid amiodarone interaction by reducing digoxin dose 50% when initiating amiodarone.

DIGOXIN IMMUNE FAB (Fragment Antigen Binding) (Digibind)

Class: Antidote to Digoxin and Digitoxin

Indications: Symptomatic digoxin toxicity or acute ingestion of unknown amount of digoxin.

Adult Dose: Depends on serum digoxin levels. One 40-mg vial binds to approximately 0.6 mg of digoxin. Dose is typically administered over 30 min.

Contraindications: Allergy only, otherwise none known.

Side Effects: Worsening of CHF, rapid ventricular response in patients with A-fib, hypokalemia; increased serum digoxin levels due to bound complexes (clinically misleading because bound complex cannot interact with receptors).

Precautions: Allergy to sheep proteins or other sheep products.

DILTIAZEM (Cardizem)

Class: Calcium Channel Blocker

Indications: To control ventricular rate in A-fib, A-flutter, and PSVT (reentry SVT) refractory to adenosine with narrow QRS complex and adequate BP.

Adult Dose: 15–20 mg (0.25 mg/kg) IV given over 2 min. May repeat in 15 min at 20–25 mg (0.35 mg/kg) IV given over 2 min. Start maintenance drip at 5–15 mg/hr and titrate to HR.

Contraindications: Drug- or poison-induced tachycardia, wide-complex tachycardia of uncertain origin, rapid A-fib and A-flutter with WPW syndrome, sick sinus syndrome, second- or third-degree AV block (unless a functional artificial pacemaker is present), hypotension with systolic BP less than 90 mm Hg.

Side Effects: Hypotension, bradycardia (including AV block), chest pain, ventricular arrhythmias, peripheral edema, flushing.

Precautions: Severe hypotension in patients receiving beta blockers and in patients with hepatic dysfunction, renal disease.

DOPAMINE (Intropin)

Class: Vasopressor, Inotropic, Adrenergic Agonist

Indications: Symptomatic bradycardia and hypotension, cardiogenic shock, CHF.

Adult Dose: Continuous infusions (titrate to patient response): Low dose 1–5 mcg/kg/min; moderate dose 5–10 mcg/kg/min (cardiac doses); high dose 10–20 mcg/kg/min (vasopressor doses). Mix 400 mg/250 mL in normal saline, lactated Ringer's solution, or D5W (1600 mcg/mL).

Pediatric Dose: 2–20 mcg/kg per min IV/IO infusion; titrate to desired effect.

Contraindications: Hypersensitivity to sulfites, pheochromocytoma, VF.

Side Effects: Tachyarrhythmias, ectopic beats, angina, hypotension, palpitations, vasoconstriction, dyspnea, nausea and vomiting.

DOPAMINE *continued*

Precautions: Hypovolemia, MI. Adjust dosage in elderly patients and in those with occlusive vascular disease. Ensure adequate volume resuscitation before infusion. Taper slowly. Do not mix with sodium bicarbonate. Use care with peripheral administration; infiltration can cause tissue necrosis. A central line is preferred.

EPINEPHRINE (Adrenalin)

Class: Adrenergic Agonist

Indications: Cardiac arrest: PEA, asystole, pulseless VT, VF; hypotension with severe bradycardia.

Adult Dose: *Cardiac arrest* 1 mg IV/IO (10 mL of 1:10,000 solution) given every 3–5 min as needed; follow each dose with 20 mL IV flush. Give 2.0–2.5 mg diluted in 10 mL normal saline if administering by ET tube. *Profound bradycardia or hypotension* 2–10 mcg/min IV—add 1 mg (1 mL of a 1:1000 solution) to 500 mL normal saline or D5W.

Pediatric Dose: *Cardiac arrest or symptomatic bradycardia* 0.01 mg/kg (0.1 mL/kg) 1:10,000 IV/IO every 3–5 min (maximum 1 mg; 1 mL). Give 0.1 mg/kg (0.1 mL/kg) 1:1000 diluted in 3–5 mL normal saline if administering by ET tube. Repeat every 3–5 min.

Contraindications: Hypersensitivity to adrenergic amines, hypovolemic shock, coronary insufficiency.

Side Effects: Angina, HTN, tachycardia, palpitations, VT, VF, nervousness, restlessness, tremors, weakness, headache, dizziness, sweating, nausea.

Precautions: Use caution in HTN and increasing heart rate (may cause increased myocardial oxygen demand). Higher doses can contribute to post-arrest cardiac impairment, but they may be required to treat poison- or drug-induced shock. Avoid mixing with alkaline solutions.

FIBRINOLYTIC AGENTS

Class: Thrombolytic, Fibrinolytic

Common Agents: Alteplase (**Activase, t-PA**), Anistreplase (**Eminase**), Reteplase (**Retavase**), Streptokinase (**Streptase**), Tenecteplase (**TNKase**).

Indications: Acute MI symptoms within the last 12 hr. Alteplase is the only fibrinolytic agent approved for acute ischemic stroke and must be started less than 3 hr from the onset of symptoms.

Adult Dose: See individual order and drug for route and dosage.

Contraindications: Active internal bleeding within 21 days (except menses), neurovascular event within 3 months, major surgery or trauma within 2 weeks, aortic dissection, severe (uncontrolled) HTN, bleeding disorders, prolonged CPR, lumbar puncture within 1 week.

Side Effects: Hypotension, reperfusion arrhythmias, heart failure, headache, increased bleeding time, deep or superficial hemorrhage, flushing, urticaria, anaphylaxis.

Precautions: Use cautiously in patients with severe renal or hepatic disease. Initiate bleeding precautions. Monitor patient for bleeding complications.

FUROSEMIDE (Lasix)

Class: Diuretic, Loop Diuretic

Indications: Congestive heart failure with acute pulmonary edema, hypertensive crisis, post-arrest cerebral edema, hepatic or renal disease.

Adult Dose: 0.5–1.0 mg/kg IV given over 1–2 min; may repeat at 2 mg/kg IV given over 1–2 min.

Pediatric Dose: 1 mg/kg IV/IO (usual maximum 20 mg if not chronically on loop diuretic).

Contraindications: Hypersensitivity (cross-sensitivity with thiazides and sulfonamides may occur), uncontrolled electrolyte imbalance, hepatic coma, anuria, hypovolemia.

Side Effects: Severe dehydration, hypovolemia, hypotension, hypokalemia, hypomagnesemia, hyponatremia, hypochloremia, hyperglycemia, dizziness, ototoxicity.

Precautions: Use cautiously in severe liver disease accompanied by cirrhosis or ascites, electrolyte depletion, diabetes mellitus, pregnancy, lactation. Risk for ototoxicity with increased dose or rapid injection. Monitor electrolytes closely.

IBUTILIDE (Corvert)

Class: Antiarrhythmic

Indications: Supraventricular tachycardia, including A-fib and A-flutter; most effective for conversion of A-fib or A-flutter of short duration (≤ 48 hr).

IBUTILIDE *continued*

Adult Dose: *Patients weighing 60 kg or more* 1 mg IV given over 10 min; may repeat the same dose in 10 min if arrhythmia does not terminate. *Patients weighing less than 60 kg* 0.01 mg/kg IV given over 10 min; may repeat the same dose in 10 min if arrhythmia does not terminate.

Contraindications: Known hypersensitivity, history of polymorphic VT, QTc greater than 440 msec.

Side Effects: Unsustained or sustained monomorphic or polymorphic VT, torsade de pointes, AV block, CHF, HTN, headache, hypotension, nausea and vomiting.

Precautions: Monitor ECG for 4–6 hr after administration, with a defibrillator nearby. Correct electrolyte abnormalities before use. If A-fib has lasted longer than 48 hr, anticoagulation is required before conversion with ibutilide.

ISOPROTERENOL (Isuprel)

Class: Sympathomimetic, Beta-Adrenergic Agonist

Indications: Medically refractory symptomatic bradycardia when transcutaneous or transvenous pacing is not available, refractory torsade de pointes unresponsive to magnesium, bradycardia in heart transplant patients, beta blocker poisoning.

Adult Dose: IV infusion: mix 1 mg/250 mL in normal saline, lactated Ringer's solution, or D5W, run at 2–10 mcg/min, and titrate to patient response. In torsade de pointes, titrate to increase heart rate until VT is suppressed.

Contraindications: Cardiac arrest, hypersensitivity to drug or sulfites, digitalis intoxication, angina, concurrent use with epinephrine (can cause VF or VT), poison- or drug-induced shock (*exception:* beta blocker poisoning).

Side Effects: Arrhythmias, cardiac arrest, hypotension, angina, anxiety, tachycardia, palpitations, skin flushing.

Precautions: May increase myocardial ischemia, tachycardia, restlessness. High doses are harmful except in beta blocker overdose.

LIDOCAINE (Xylocaine)

Class: Antiarrhythmic, Local Anesthetic

Indications: Ventricular fibrillation or pulseless VT, stable VT (with pulses), wide-complex tachycardia of uncertain origin.

Adult Dose: *Cardiac arrest from VF or VT* 1.0–1.5 mg/kg IV/IO (or 2–4 mg/kg via ET tube); may repeat 0.50–0.75 mg/kg IV/IO every 5–10 min, maximum dose 3 mg/kg. *Stable VT, wide-complex tachycardia of uncertain origin* 0.50–0.75 mg/kg and up to 1.0–1.5 mg/kg; may repeat 0.50–0.75 mg/kg every 5–10 min, maximum total dose 3.0 mg/kg. If conversion is successful, start an IV infusion of 1–4 mg/min (30–50 mcg/kg/min) in normal saline or D5W.

Pediatric Dose: 1 mg/kg IV/IO bolus. Give 2–3 mg/kg diluted in 3–5 mL normal saline if administering by ET tube. Maintenance: 20–50 mcg/kg per min IV/IO infusion (repeat bolus [1 mg/kg IV/IO] when infusion is initiated if bolus has not been given within previous 15 min).

Contraindications: Prophylactic use in acute MI, advanced AV block without functioning artificial pacemaker, hypotension, WPW syndrome, hypersensitivity to amide local anesthetics.

Side Effects: Confusion, agitation, anxiety, tinnitus, tremors, hallucinations, seizures, bradycardia, hypotension, cardiovascular collapse, respiratory arrest.

Precautions: Congestive heart failure, respiratory depression, shock. Reduce maintenance dose (not loading dose) in presence of impaired liver function or left ventricular dysfunction or in the elderly. Stop infusion if signs of CNS toxicity develop.

MAGNESIUM SULFATE

Class: Electrolyte, Antiarrhythmic

Indications: Torsade de pointes.

Adult Dose: *Torsade de pointes (cardiac arrest—pulseless VT)* 1–2 g IV (2–4 mL of a 50% solution) diluted in 10 mL of D5W over 5–20 min. *Torsade de pointes (non-cardiac arrest with pulses)* load with 1–2 g mixed in 50–100 mL of D5W infused over 5–60 min IV, then infuse 0.5–1.0 g/hr IV (titrate to control torsade).

Pediatric Dose: *Torsade de pointes (cardiac arrest—pulseless VT)* 25–50 mg/kg IV/IO bolus. *Torsade de pointes (non-cardiac arrest with pulses)* 25–50 mg/kg IV/IO over 10–20 min.

Contraindications: Hypermagnesemia, hypocalcemia, renal disease, AV block, toxemia of pregnancy 2 hr before delivery.

MAGNESIUM SULFATE *continued*

Side Effects: Hypotension, bradycardia, cardiac arrest, respiratory depression, altered level of consciousness (LOC), flushed skin, diaphoresis, hypocalcemia, hyperkalemia, hypophosphatemia.

Precautions: Renal insufficiency, occasional fall in BP with rapid administration. Monitor serum magnesium levels.

MORPHINE SULFATE

Class: Opiate Narcotic Analgesic

Indications: Chest pain unrelieved by nitroglycerin, CHF and dyspnea associated with pulmonary edema.

Adult Dose: 2–4 mg IV (given over 1–5 min) every 5–30 min if hemodynamically stable; may repeat dose of 2–8 mg at 5- to 15-min intervals.

Contraindications: Hypersensitivity, heart failure due to chronic lung disease, respiratory depression, hypotension. Avoid in patients with right ventricular infarction.

Side Effects: Respiratory depression, hypotension, nausea and vomiting, bradycardia, altered LOC, seizures.

Precautions: Administer slowly and titrate to effect. Reverse with naloxone (0.4–2.0 mg IV) if necessary. Use caution in cerebral edema and pulmonary edema with compromised respiration. Use caution with hypovolemic patients; be prepared to administer volume.

NITROGLYCERIN (Nitrostat, Nitrolingual [Pump spray])

Class: Antianginal, Nitrate, Vasodilator

Indications: Acute coronary syndrome (ACS), cardiogenic shock, angina, CHF associated with acute MI, hypertensive urgency with ACS.

Adult Dose: Sublingual route, 0.3–0.4 mg (1 tablet); repeat every 3–5 min, maximum 3 doses/15 min. Aerosol spray for 0.5–1.0 sec at 3- to 5-min intervals (provides 0.4 mg/dose), maximum 3 sprays/15 min. Intravenous bolus administration at 12.5–25.0 mcg (if no sublingual or spray used). Intravenous infusion: Begin at 5–20 mcg/min and titrate to effect. Increase by 5–10 mcg/min every 5–10 min until desired effect. IV solution can be mixed at 25 mg/250 mL (100 mcg/mL) in D5W.

Pediatric Dose: 0.25–0.50 mcg/kg per min IV/IO infusion, may increase by 0.5–1 mcg/kg per min every 3–5 min as needed to 1–5 mcg/kg per min (maximum 10 mcg/kg per min); adolescents: 10–20 mcg/min, increase by 5–10 mcg/min every 5–10 min as needed (maximum 200 mcg/min).

Contraindications: Hypersensitivity, systolic BP less than 90 mm Hg; severe bradycardia or severe tachycardia associated with hypotension; sildenafil (**Viagra**), vardenafil (**Levitra**) within 24 hr, tadalafil (**Cialis**) within 48 hr; right ventricular infarction.

Side Effects: Hypotension with reflex tachycardia, paradoxical bradycardia, syncope, headache, flushed skin.

Precautions: Do not mix with other medications; titrate IV to maintain systolic BP above 90 mm Hg. Mix only in glass IV bottles and infuse only through tubing provided by manufacturer; standard polyvinyl chloride tubing can bind up to 80% of the medication, making it necessary to infuse higher doses. Do not shake aerosol spray (affects metered dose).

OXYGEN

Class: Gas

Indications: Cardiopulmonary emergencies with shortness of breath and chest pain, cardiac or respiratory arrest, hypoxemia.

Adult and Pediatric Dose: Nasal cannula 1–6 L/min (21%–44% oxygen), Venturi mask 4–12 L/min (24%–50% oxygen), simple mask 5–8 L/min (40%–60% oxygen), partial rebreathing mask 6–10 L/min (35%–60% oxygen), non-rebreathing mask 6–15 L/min (60%–100% oxygen), bag-valve-mask 15 L/min (95%–100% oxygen).

Contraindications: None reported.

Side Effects: Drying of respiratory mucosa, possible bronchospasm if oxygen is extremely cold and dry. Oxygen supports combustion and can fuel a fire.

Precautions: Respiratory arrest in patients with hypoxic respiratory drive (rare). The patient needs an airway and adequate ventilation before oxygen is effective.

PROCAINAMIDE (Pronestyl)

Class: Antiarrhythmic

Indications: Recurrent VT or VF, PSVT refractory to adenosine and vagal stimulation, rapid A-fib with WPW syndrome, stable wide-complex tachycardia of uncertain origin, maintenance after conversion.

Adult Dose: 20 mg/min IV infusion or up to 50 mg/min under urgent conditions, maximum 17 mg/kg loading dose. Maintenance IV infusion: mix 1 g/250 mL (4 mg/mL) in normal saline or D5W, run at 1–4 mg/min.

PROCAINAMIDE *continued*

Pediatric Dose: Atrial flutter, SVT, VT (with pulses) 15 mg/kg IV/IO load over 30–60 min (do not use routinely with amiodarone).

Contraindications: Second- and third-degree AV block (unless a functioning artificial pacemaker is in place), prolonged QT interval, torsade de pointes, hypersensitivity.

Side Effects: Hypotension, widening QRS, arrhythmias, headache, nausea and vomiting, flushed skin, seizures, ventricular arrhythmias, AV block, cardiovascular collapse, arrest.

Precautions: Monitor BP every 2–3 min while administering procainamide. If QRS width increases by 50% or more, or if systolic BP decreases to less than 90 mm Hg, stop the drug. Monitor for prolonged PR interval, heart block, and QT prolongation. May precipitate or exacerbate CHF. Reduce the total dose to 12 mg/kg and maintenance infusion to 1–2 mg/min if cardiac or renal dysfunction is present. Use cautiously in myasthenia gravis, in hepatic or renal disease, and with drugs that prolong the QT interval (e.g., amiodarone, sotalol).

SODIUM BICARBONATE

Class: Alkalinizing Agent, Buffer

Indications: Known preexisting hyperkalemia, bicarbonate-responsive metabolic acidosis, prolonged resuscitation with effective ventilation.

Adult Dose: 1 mEq/kg given rapidly; may repeat 0.5 mEq/kg every 10 min.

Pediatric Dose: 1 mEq/kg IV/IO slow bolus.

Contraindications: Metabolic and respiratory alkalosis, hypocalcemia, hypokalemia, hypercarbic acidosis.

Side Effects: Hypokalemia, hypocalcemia, hypernatremia, metabolic alkalosis, edema, seizures, tetany, exacerbation of CHF.

Precautions: Congestive heart failure, renal disease, cirrhosis, toxemia, concurrent corticosteroid therapy. Not recommended for routine use in cardiac arrest patients because adequate ventilation and CPR are the major “buffer agents” in cardiac arrest. Incompatible with many drugs; flush the line before and after administration.

VASOPRESSIN (Pitressin)

Class: Vasopressor, Hormone

Indication: Cardiac arrest: an alternative to epinephrine in shock-refractory VF and pulseless VT, PEA, and asystole.

Adult Dose: *Cardiac arrest* 40 units IV single dose to replace first or second dose of epinephrine as an alternative.

Contraindications: Hypersensitivity, seizures, heart failure, asthma, coronary artery disease, migraine, allergy to beef or pork protein, chronic renal failure with increased blood urea nitrogen (BUN).

Side Effects: Bradycardia, HTN, angina, MI, arrhythmias, dizziness, headache, nausea and vomiting, abdominal cramps, diaphoresis, bronchoconstriction, anaphylaxis.

Precautions: Coronary artery disease (may precipitate angina or MI), renal impairment, seizure disorders, asthma, vascular disease.

VERAPAMIL (Calan, Isoptin)

Class: Calcium Channel Blocker, Antiarrhythmic, Antihypertensive

Indications: Paroxysmal supraventricular tachycardia (with narrow QRS and adequate BP) refractory to adenosine, rapid ventricular rates in A-fib, A-flutter, or MAT.

Adult Dose: 2.5–5.0 mg IV over 2 min; may give second dose, if needed, of 5–10 mg IV in 15–30 min, maximum dose 20 mg. An alternative second dose is 5 mg IV every 15 min, maximum dose 30 mg.

Contraindications: Atrial fibrillation with WPW syndrome, wide-complex tachycardia of uncertain origin, second- or third-degree AV block (unless a functioning artificial pacemaker is in place), sick sinus syndrome, hypotension, severe CHF, cardiogenic shock.

Side Effects: Hypotension, exacerbation of CHF with left ventricular dysfunction, bradycardia, AV block, constipation, peripheral edema.

Precautions: Concurrent oral beta blockers, CHF, impaired hepatic or renal function; may decrease myocardial contractility. In geriatric patients administer slowly over 3 min.

Common Medication Formulas

Syringe: Amount to be drawn up	$\frac{\text{Desired dose of drug} \times \text{Total volume on hand}}{\text{Total dosage of drug on hand}}$
IV: Calculating gtt/min	$\frac{\text{Volume to be infused} \times \text{Drop (gtt) factor}}{\text{Total time in minutes to infuse drug}}$
IV: Calculating infusion rate	$\frac{\text{Volume on hand} \times \text{gtt factor} \times \text{Desired dose}}{\text{Total dosage of drug on hand}} = \text{gtt/min}$ <p>Example: Administer 2 mg/min of lidocaine. To prepare the infusion mix 2 g of lidocaine in 500 mL of D5W with a drip set of 60 gtts/mL. Calculate the infusion rate.</p> $30 \text{ gtts/min} = \frac{500 \text{ mL} \times 60 \text{ gtts/mL} \times 2 \text{ mg/min}}{2000 \text{ mg}}$
IV: Rate of an existing IV	<ol style="list-style-type: none"> Count drops (gtt)/minute and multiply by 60 min. Divide result by the drop (gtt) factor being used.


IV Fluid Drip Rate Table (gtt/minute)

Rate: (mL/hr) →	TKO	50	75	100	125	150	175	200	250
10 gtt/mL set	5	8	13	17	21	25	29	33	42
12 gtt/mL set	6	10	15	20	25	30	35	40	50
15 gtt/mL set	8	13	19	25	31	37	44	50	62
20 gtt/mL set	10	17	25	33	42	50	58	67	83
60 gtt/mL set	30	50	75	100	125	150	175	200	250

Note: TKO (to keep open) is 30 mL/hr.

Universal Formula—Figure Out Drip Rates and Drug Amounts

109

<p>1a Enter the amount of drug that is ordered.</p> <p>mg, g, µg, etc. ()</p>	X	<p>Enter weight in kg if applicable; otherwise, leave blank.</p> <p>kg</p>	X	<p>For mL/hr only (no drugs), use the boxes highlighted in yellow [(Vol x gtt)/Time].</p> <p>Volume mL</p>	<p>IV Push Orders</p> <p>Follow step 1 to find volume to be drawn up in a syringe.</p> 
<p>1b When medication is part of the equation, enter the total amount of drug you have on hand here. →</p> <p>mg, g, µg, etc. ()</p>				<p>2 Multiply step 1 by drip factor.</p> <p>Drip Factor (gtt/mL)</p>	
<p>1c Then enter the total volume on hand here. →</p>					

<p>To figure out the running time (mL/hr) on an existing IV, first count the drops per minute. Then multiply that amount by 60 and divide the result by the drip factor being used.</p>	<p>3 Time minutes</p>	<p>Divide the results obtained in steps 1 and 2 by the number of minutes over which the medication or fluid has been ordered.</p>
---	------------------------------	---

	=		=	
				gtt/min

<p>Legend</p> <p>mL/hr = [(Vol x gtt)/time] mg/min = steps 1a-c, 2, 3 mg/kg/min = fill every box Syringe = steps 1a-c</p>

Note: The abbreviation mcg (microgram) means the same as µg (used in the above formula); mcg is the most commonly used to prevent medication errors.

Emergency Medical Skills

Defibrillation

Indications: Ventricular fibrillation or pulseless VT.

Energy Levels: Adult: With monophasic energy levels, deliver the first shock at 360 J. If using a biphasic manual defibrillator, use the manufacturer's device-specific energy levels, usually 120–200 J. Continue at a monophasic energy level of 360 J for further shocks. With a biphasic manual defibrillator, use the device-specific energy levels, usually 120–200 J for further shocks. Use device-specific energy levels for an automated external defibrillator (AED).

Child(1–8 yr): Deliver the first shock at 2 J/kg for a monophasic or biphasic manual defibrillator; use 4 J/kg for subsequent shocks. Use device-specific energy levels for an automated external defibrillator (AED).

Application: Use handheld paddles or remote adhesive pads. Always use a conducting gel with paddles and apply firm pressure to the chest to ensure good skin contact. Dry moisture off skin; shave excessive hair. Use pediatric paddles or pads in a child.

Methods: Manual or automated.

Precautions: Place paddles and pads several inches away from an implanted pacemaker.

♥ **Clinical Tip:** Defibrillation may be used on children (1–8 yr). Always use pediatric paddles or pads and follow pediatric protocols. Data are insufficient to allow a recommendation for or against the use of manual defibrillation or AEDs for infants younger than 1 yr. Refer to your local protocols for the use of defibrillation on an infant.

♥ **Clinical Tip:** Currently there is insufficient evidence to recommend a different dose for biphasic than for monophasic defibrillation in children.

Manual Defibrillation

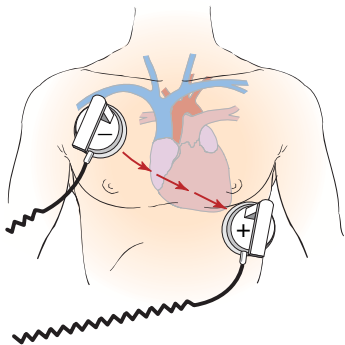
A manual defibrillator is used to stop or interrupt chaotic electrical activity and restore a normal heart rhythm. For a patient experiencing sudden cardiac arrest, first assess for responsiveness, respiration, and pulse. If the ECG tracing is available, use it to verify that the rhythm is either VF or pulseless VT, and then manually deliver an electric shock to the heart.

Procedure

1. Verify that the patient is in cardiac arrest, with no pulse or respiration. Have someone provide CPR while the defibrillator is obtained and placed next to the patient.
2. Paddles: Use conducting gel and place on the apex (lower left chest, midaxillary) and sternum (right of sternum, midclavicular).
Pads: Place in locations specified for paddles.
3. Turn on the defibrillator; verify that all cables are connected.
4. Turn "Lead select" to "Paddles" or "Defibrillator."
5. **Energy levels:** Adult: Set the energy initially to a monophasic level of 360 J. With a biphasic manual defibrillator, use the manufacturer's device-specific energy levels, usually 120–200 J. Use the same energy level for subsequent shocks. Child (1–8 yr): Select the energy level for the first shock to 2 J/kg for a monophasic or biphasic manual defibrillator. Use 4 J/kg for subsequent shocks.
6. Verify rhythm as VF or pulseless VT.
7. Say, "Charging defibrillator, stand clear!"
8. Charge the defibrillator.
9. Say, "I'm going to shock on three. One, I'm clear; two, you're clear; three, everybody's clear." Perform a visual sweep to ensure all rescue personnel are clear of the patient, bed, and equipment.

Continued

10. Discharge the defibrillator, give CPR for 2 min, reassess the rhythm, and refer to appropriate Advanced Cardiac Life Support (ACLS) or Pediatric Advanced Life Support (PALS) protocol.



Placement of paddles for defibrillation

Automated External Defibrillation

An automated external defibrillator (AED) is a small, lightweight device used by both professionals and laypersons to assess heart rhythm by computer analysis. Using voice and visual prompts, it administers an electric shock, if necessary, to restore a normal rhythm in patients with sudden cardiac arrest. A shock is administered only if the rhythm detected is VF or pulseless VT. Automated external defibrillators are available from medical device manufacturers and local pharmacies. Although the AEDs all operate in basically the same way, they may vary from model to model. Be sure to follow the manufacturer's recommendations.

Indications: Ventricular fibrillation or pulseless VT in adults and children (1–8 yr). Insufficient data are available to allow a recommendation for or against the use of AEDs for infants younger than 1 yr. Refer to your local protocols for the use of an AED on an infant.

Dose: The AED will automatically select the energy dose for each defibrillation. Some devices are equipped with pediatric systems that include a pad-cable system or a key to reduce the delivered energy to a suitable dose for children. Never use a pediatric pad on an adult. The energy will not be sufficient.

Procedure

1. Verify that the patient is in cardiac arrest, with no pulse or respiration. Have someone provide CPR while the AED is obtained and placed next to the patient.
2. Turn on the AED. Follow the voice prompts and visual messages.
3. Open the package of adhesive electrode pads and attach pads to the patient's bare chest.
4. Use adult pads for an adult and pediatric pads for a child. If there are no pediatric pads available, you may use adult pads on a child, but be sure the pads do not touch.
5. Attach one pad to the right sternal border (superior–anterior right chest) and place the second pad over the left apex (inferior–lateral left chest). Alternatively, follow the diagrams on each of the AED electrodes.
6. Attach the pads to the patient cables.
7. Clear the patient and stop CPR.
8. The AED may automatically analyze the patient's rhythm or may be equipped with an "Analyze" button.
9. If a shock is advised, say, "I'm going to shock on three. One, I'm clear; two, you're clear; three, everybody's clear." Perform a visual sweep to ensure rescue personnel are not touching the patient or equipment. Press the "Shock" button.
10. Once the shock is delivered, continue CPR beginning with chest compression.
11. After about 2 min of CPR the AED will prompt you with further verbal and visual cues.

♥ **Clinical Tip:** A fully automated AED analyzes the rhythm and delivers a shock, if one is indicated, without operator intervention.

♥ **Clinical Tip:** A semiautomated AED analyzes the rhythm and tells the operator that a shock is indicated. If it is, the operator initiates the shock.

Cardioversion (Synchronized)

Indications: Unstable tachycardias with a perfusing rhythm. The patient may present with an altered LOC, dizziness, chest pain, or hypotension.

Energy Levels: Adult: With monophasic equipment, use energy levels of 100 J, 200 J, 300 J, and 360 J. Biphasic equipment supports an initial dose of 100–120 J with escalation as needed. Child (1–8 yr): The initial energy level is 0.5–1 J/kg. Second and subsequent energy levels are 2 J/kg.

Application: Use adult or pediatric handheld paddles or remote adhesive pads. Always use a conducting gel with paddles. Dry moisture off skin; shave excessive hair. For conscious patients, explain the procedure and use a medication for sedation.

Methods: Place the defibrillator in synchronized (Sync) mode. Charge to appropriate level. Say, “I’m going to shock on three. One, I’m clear; two, you’re clear; three, everybody’s clear.” Perform a visual sweep and press the “Shock” button. Reassess the patient and treat according to the appropriate ACLS or PALS protocol.

Precautions: Reactivate the Sync mode after each attempted cardioversion; defibrillators default to the unsynchronized mode. Place paddles and pads several inches away from an implanted pacemaker.

♥ **Clinical Tip:** The Sync mode delivers energy just after the R wave to avoid stimulation during the refractory, or vulnerable, period of the cardiac cycle, when a shock could potentially produce VF.

♥ **Clinical Tip:** Make sure the Sync button is activated before shock.

♥ **Clinical Tip:** Currently there is insufficient evidence to recommend a different dose for biphasic than for monophasic cardioversion in children.

Transcutaneous Pacing

Indications: Symptomatic bradycardia (with a pulse) unresponsive to atropine, bradycardia with ventricular escape rhythms, symptomatic second-degree AV block type II, or third-degree AV block.

Pacing Modes: *Demand-mode (synchronous)* pacemakers sense the patient’s heart rate and pace only when the heart rate falls below the level set by the clinician. *Fixed-mode (asynchronous)* pacemakers cannot

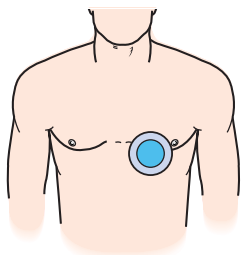
sense the heart rate and always operate at the rate set by the clinician. Rate selections vary between 30 and 180 bpm. Output is adjustable between 0 and 200 mA. Pulse duration varies from 20 to 40 ms.

Application: Pacemaker pads work most effectively if placed in an anterior–posterior position on the patient.

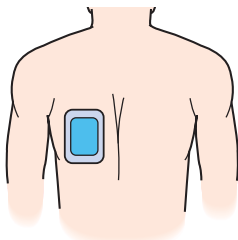
Contraindications: Not effective in VF, pulseless VT, or asystole.

Side Effects: Chest muscle contraction, burns, and chest discomfort.

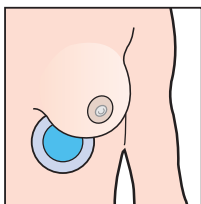
Precautions: Dry moisture off skin, shave excessive chest hair, and make sure pads have good skin contact to achieve capture and avoid burns.



Anterior



Posterior



Female patients:
Position electrode
under breast

Placement of anterior-posterior pacemaker pads

Carotid Sinus Massage (Vagal Maneuver)

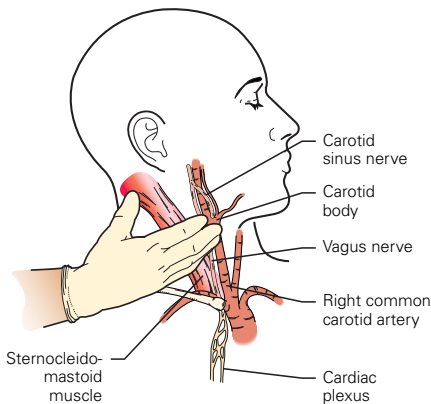
Indications: Can increase vagal nerve stimulation and slow SVT, or even convert SVT to NSR, without severe hemodynamic compromise.

Method: Place the patient in a supine position, head tilted to either side with the neck hyperextended. Auscultate the artery with a stethoscope for the presence of bruits (sounds indicating the artery is occluded). If none are heard, place your index and middle fingers over the carotid artery just below the angle of the jaw, as high on the neck as possible. Massage the artery for 5 to 10 sec by pressing it firmly against the vertebral column and rubbing. Massage only one artery at a time.

Contraindications: Unequal carotid pulses, carotid bruits, cervical spine injury, or history of cerebrovascular accident or carotid atherosclerosis.

Side Effects: Slow HR or AV block, PVCs, VT, VF, syncope, seizure, hypotension, nausea or vomiting, stroke.

Precautions: Be sure the patient is receiving oxygen and an IV is in place. Never massage both arteries simultaneously.



Carotid sinus massage

Health-Care Provider Guidelines for Cardiopulmonary Resuscitation (CPR)

CPR Method	Compression/ Ventilation Ratio	Rate of Compressions (min)	Depth of Compressions	Pulse Check (artery)	Hand Position for Compressions
Adult, 1 rescuer	30:2	100	1.5–2.0 in	Carotid	Heels of 2 hands over center of chest between nipples
Adult, 2 rescuers	30:2	100	1.5–2.0 in	Carotid	Heels of 2 hands over center of chest between nipples
Child, 1 rescuer	30:2	100	$\frac{1}{3}$ – $\frac{1}{2}$ depth of chest	Carotid	Heel of 1 or 2 hands over center of chest between nipples
Child, 2 rescuers	15:2	100	$\frac{1}{3}$ – $\frac{1}{2}$ depth of chest	Carotid	Heel of 1 or 2 hands over center of chest between nipples
Infant, 1 rescuer	30:2	100	$\frac{1}{3}$ – $\frac{1}{2}$ depth of chest	Brachial Femoral	2 fingers on middle sternum, just below nipple line
Infant, 2 rescuers	15:2	100	$\frac{1}{3}$ – $\frac{1}{2}$ depth of chest	Brachial Femoral	2 thumbs–encircling hands just below nipple line
Newborn	3:1	120	$\frac{1}{3}$ depth of chest	Brachial Femoral	2 fingers over lower third of sternum

CPR: Adult (adolescent [puberty] and older)

1. Ensure that the scene is safe. **Check for unresponsiveness.** Gently tap the person's shoulder. Ask, "Are you okay?"
2. **In a sudden collapse**, if there is no response and you are alone, summon help, call a code, or phone 911 and get an AED, if available. Send a second rescuer, if available, for help.
3. **Position the person supine** on a hard, flat surface.
4. **Open the airway** by the head tilt–chin lift method or, if spinal injury is suspected, use the jaw thrust method, if possible.
5. **Look, listen, and feel for adequate breathing (no more than 10 sec).**
6. If the person is not breathing, **begin rescue breaths.** Using a bag-valve-mask device or face mask, **give 2 breaths (1 sec each)** with sufficient volume to cause the chest to rise. Do not over-ventilate. Note: If the chest does not rise, reposition the head, chin, and jaw, and attempt 2 more breaths. If the chest still does not rise, follow instructions for unconscious adult with an obstructed airway (p 124).
7. **Assess the carotid pulse and look for other signs of circulation** (no more than 10 sec). If signs of circulation are present but the person is still not breathing, give rescue breaths at a rate of 10–12 breaths/min (1 breath every 5–6 sec).
8. If a pulse and signs of circulation are not present, **begin compressions.** Place the heel of one hand over the center of the chest between the nipples; place the heel of your other hand over the first. Firmly compress the chest 1.5–2.0 in. Give 30 compressions at a rate of 100/min.
9. **Continue to give 2 breaths followed by 30 compressions.** After the fifth cycle of 30:2 (2 min), **recheck the pulse** and look for other signs of circulation (no more than 10 sec). If circulation is not present, use the AED. Follow the instructions on how to use an AED on page 112. If an AED is unavailable, resume CPR, starting with compressions in cycles of 30:2. After each fifth cycle of 30:2 (2 min), recheck the pulse and look for other signs of circulation (no more than 10 sec).
10. If circulation resumes but breathing does not or is inadequate, continue rescue breathing at 10–12 breaths/min.
11. If adequate breathing and circulation resume, place the person in the recovery position and monitor until help arrives.

CPR: Child (1 yr to adolescent [puberty])

1. Ensure that the scene is safe. **Check for unresponsiveness.** Gently tap child's shoulder. Ask, "Are you okay?"
2. If no response send a second rescuer, if available, for help.
3. If you are alone, begin the steps for CPR.
4. **Position the child supine** on a hard, flat surface.
5. **Open the airway** by the head tilt–chin lift method or, if spinal injury is suspected, use the jaw thrust method, if possible.
6. **Look, listen, and feel for adequate breathing** (no more than 10 sec).
7. If the child is not breathing, **begin rescue breaths.** Using a bag-valve-mask device or face mask, give 2 breaths (1 sec each) with sufficient volume to make the chest rise. Do not over-ventilate.
Note: If the chest does not rise, reposition the head, chin, and jaw and attempt 2 more breaths. If the chest still does not rise, follow instructions for unconscious child with an obstructed airway (p 125).
8. **Assess the carotid pulse and look for other signs of circulation** (no more than 10 sec). If signs of circulation are present but the child is not breathing, give rescue breaths at a rate of 12–20 breaths/min.
9. If pulse and signs of circulation are not present or the heart rate is less than 60 bpm with signs of poor perfusion, **begin compressions.** Place the heel of 1 or 2 hands over the center of the chest between the nipples. Firmly compress chest at $\frac{1}{3}$ to $\frac{1}{2}$ depth of chest. Give 30 compressions. Compress at a rate of 100 per min.
10. **Continue to give 2 breaths followed by 30 compressions.** After the fifth cycle of 30:2 (2 min), **recheck the pulse** and look for other signs of circulation (no more than 10 sec). If you are still alone and no signs of circulation are present, **summon help, call a code, or phone 911 and get an AED, if available.**
11. Return to the child. If circulation is still not present, continue CPR until the AED is available. Follow the instructions on how to use an AED on page 112. If an AED is unavailable, continue to give 2 breaths followed by 30 compressions. After each fifth cycle of 30:2 (2 min), recheck pulse and look for other signs of circulation.
12. If circulation resumes but breathing does not, continue rescue breathing at 12–20 breaths/min (1 breath every 3–5 sec).
13. If adequate breathing and circulation resume, place the child in the recovery position and monitor until help arrives.

CPR: Infant (younger than 1 yr)

1. Ensure that the scene is safe. **Check for unresponsiveness.** Gently rub the infant's back or chest or tap the feet. Never shake an infant. Ask, "Are you okay?"
2. If no response send a second rescuer, if available, for help.
3. If you are alone, begin the steps for CPR.
4. **Position the infant supine** on a hard, flat surface.
5. **Open the airway** by the head tilt–chin lift method. If spinal injury is suspected, use the jaw thrust method, if possible.
6. **Look, listen, and feel for adequate breathing** (no more than 10 sec).
7. If the infant is not breathing, begin rescue breaths. Using a bag-valve-mask device or face mask, **give 2 breaths (1 sec each) with sufficient volume to make the chest rise.** Do not over-ventilate. Note If the chest does not rise, reposition the head, chin, and jaw and give 2 more breaths. If the chest still does not rise, follow instructions for unconscious infant with an obstructed airway (p 126).
8. **Assess the brachial or femoral pulse and look for other signs of circulation** (no more than 10 sec). If signs of circulation are present but the infant is still not breathing, continue rescue breaths at the rate of 12–20 breaths/min (1 breath every 3–5 sec).
9. If pulse and signs of circulation are not present or the heart rate is less than 60 bpm with signs of poor perfusion, **begin compressions.** Place two fingers of one hand on the sternum just below the nipple line. Firmly compress the chest by $\frac{1}{3}$ to $\frac{1}{2}$ its depth. Give 30 compressions. Compress at a rate of 100 per min.
10. **Continue to give 2 breaths followed by 30 compressions.** After the fifth cycle of 30:2 (2 min), **recheck the pulse** and look for other signs of circulation (no more than 10 sec). If you are still alone and no signs of circulation are present, **summon help, call a code, or phone 911.**
11. If circulation is still not present, continue CPR. After each fifth cycle of 30:2 (2 min), recheck the pulse and look for other signs of circulation (no more than 10 sec).
12. If circulation resumes but breathing does not or is inadequate, continue rescue breathing at 12–20 breaths/min.
13. If adequate breathing and circulation resume, place the infant in the recovery position and monitor until help arrives.

Obstructed Airway: Conscious Adult or Child (1 yr or older)

Clinical Presentation

- Grabbing at the throat with one or both hands
 - Inability to speak; high-pitched crowing sounds
 - Wheezing, gagging, ineffective coughing
1. **Determine that the airway is obstructed.** Ask, “Are you choking? Can you speak?”
 2. Let the person know you are going to help.
 3. **Stand behind the choking person and wrap your arms around the person’s waist.** For someone who is obese or pregnant, wrap your arms around the chest.
 4. **Make a fist.** Place the thumb side of your fist in middle of the abdomen, just above the navel. Locate the middle of the sternum for obese or pregnant persons.
 5. Grasp your fist with your other hand.
 6. **Press your fist abruptly into the abdomen using an upward, inward thrust.** Use a straight thrust back for someone who is obese or pregnant.
 7. Continue thrusts until the object is dislodged or the person loses consciousness.
 8. If the person loses consciousness, treat as an unconscious adult or a child with an obstructed airway (pp 124–125).

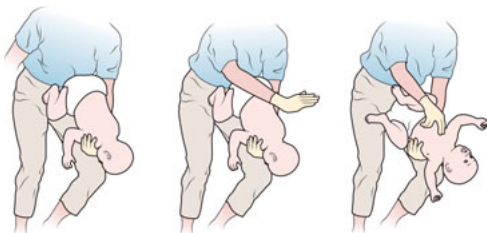

Abdominal thrusts for adult or child

Obstructed Airway: Conscious Infant (younger than 1 yr)

Clinical Presentation

- Inability to breathe or cry
 - High-pitched crowing sounds
 - Sudden wheezing or noisy breathing
1. **Determine that the airway is obstructed. Ascertain whether air exchange is poor or does not occur.**
 2. Position the infant with the chest on your forearm and the jaw between your thumb and index finger.
 3. Using your thigh or lap for support, keep the infant's head lower than the body.
 4. **Give 5 quick, forceful blows between the shoulder blades** with the heel of your other hand.
 5. Turn the infant face up on your other arm. Using your thigh or lap for support, keep the infant's head lower than the body.
 6. Place 2 fingers on the sternum just below the nipple line.
 7. **Give 5 quick thrusts downward**, depressing the chest by $\frac{1}{3}$ to $\frac{1}{2}$ its depth each time.
 8. **Continue the sequence of 5 back blows and 5 chest thrusts until the object is dislodged or the infant loses consciousness.** If the infant loses consciousness, treat as an unconscious infant with an obstructed airway (p 126).



Back blows and chest thrusts for infant

Obstructed Airway: Unconscious Adult (adolescent [puberty] and older)

Clinical Presentation

- Failure to breathe, cyanosis
- Inability to move air into lungs with rescue breaths
 1. **Establish unresponsiveness.** Gently tap the person's shoulder. Ask, "Are you OK?"
 2. If there is no response and you are alone, summon help, call a code, or phone 911 and get an AED, if available. Send a second rescuer, if available, for help.
 3. **Position the person supine** on a hard, flat surface.
 4. **Open the airway** by the head tilt–chin lift method or, if spinal injury is suspected, use the jaw thrust method, if possible.
 5. **Look, listen, and feel for adequate breathing** (no more than 10 sec).
 6. If the person is not breathing, begin rescue breaths. Using a bag-valve-mask device or face mask, give 2 breaths (1 sec each). Check to see if the chest rises.
 7. **If the chest does not rise, reposition the head, chin, and jaw, and give 2 more breaths.** If breaths cannot be delivered, perform adult CPR (p 119), beginning with compressions and using a 30:2 ratio at a rate of 100/min. Each time the airway is opened, look for an object in the person's mouth. Only use a finger sweep to remove solid material if you can see it obstructing the airway. Never perform a blind finger sweep if you do not see a foreign body in the airway.
 8. Continue CPR until breathing and circulation resume or until advanced life support measures are initiated.
 9. If circulation resumes but breathing does not or is inadequate, continue rescue breathing at 10–12 breaths/min.
 10. If adequate breathing and circulation resume, place the person in the recovery position and monitor until help arrives.

♥ **Clinical Tip:** An airway obstruction is successfully relieved if you see and remove the object or feel air movement and see the chest rise when you give breaths.

Obstructed Airway: Unconscious Child (1 yr to adolescent [puberty])

Clinical Presentation

- Failure to breathe, cyanosis
- Inability to move air into lungs with rescue breaths
 1. **Establish unresponsiveness.** Gently tap the child's shoulder. Ask, "Are you okay?"
 2. If there is no response, send a second rescuer, if available, for help.
 3. If you are alone, begin the steps for CPR.
 4. **Position the child supine** on a hard, flat surface.
 5. **Open the airway** by the head tilt–chin lift method or, if spinal injury is suspected, use the jaw thrust method, if possible.
 6. **Look, listen, and feel for adequate breathing** (no more than 10 sec).
 7. If the child is not breathing, begin rescue breaths. Using a bag-valve-mask device or face mask, give 2 breaths (1 sec each) with sufficient volume to make the chest rise. Do not over-ventilate.
 8. **If the chest does not rise, reposition the head, chin, and jaw, and attempt 2 more breaths.** If breaths cannot be delivered, perform child CPR (p 120), beginning with chest compressions and using a 30:2 ratio at a rate of 100/min. Each time the airway is opened, look for an object in the child's mouth. Only use a finger sweep to remove solid material if you can see it obstructing the airway. Never perform a blind finger sweep if you do not see a foreign body in the airway.
 9. Continue CPR until breathing and circulation resume or until advanced life support measures are initiated.
 10. After the fifth cycle, if you are still alone, summon help, call a code, or phone 911 and get an AED if available.
 11. If circulation resumes but breathing does not or is inadequate, continue rescue breathing at 12–20 breaths/min.
 12. If adequate breathing and circulation resume, place the child in the recovery position and monitor until help arrives.

♥ **Clinical Tip:** Never perform a blind finger sweep.

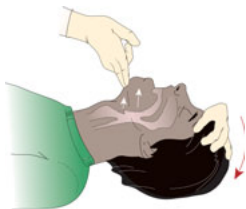Obstructed Airway: Unconscious Infant (younger than 1 yr)

Clinical Presentation

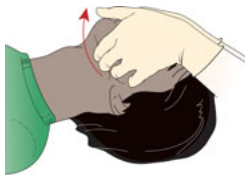
- Inability to breathe, high-pitched noises
 - Inability to move air into lungs with rescue breaths
 - Cyanosis
1. **Establish unresponsiveness.** Gently rub the infant's back or chest or tap the feet. Never shake an infant. Ask, "Are you okay?"
 2. If no response send a second rescuer, if available, for help.
 3. If you are alone, begin the steps for CPR.
 4. **Position the infant supine** on a hard, flat surface.
 5. **Open the airway** by the head tilt–chin lift method or, if spinal injury is suspected, use the jaw thrust method, if possible.
 6. **Look, listen, and feel for adequate breathing** (no more than 10 sec).
 7. If the infant is not breathing, begin rescue breaths. Using a bag-valve-mask device or face mask, give 2 breaths (1 sec each) using sufficient volume to make the chest rise. Do not over-ventilate.
 8. **If the chest does not rise, reposition the head, chin, and jaw, and attempt 2 more breaths.** If breaths cannot be delivered, perform infant CPR (p 121), beginning with chest compressions using a 30:2 ratio at a rate of 100/min. Each time the airway is opened, look for an object in the infant's mouth. Only use a finger sweep to remove solid material if you can see it obstructing the airway. Never perform a blind finger sweep if you do not see a foreign body in the airway.
 9. Continue CPR until breathing and circulation resume or until advanced life support measures are initiated.
 10. After the fifth cycle, if you are still alone, summon help, call a code, or phone 911.
 11. If circulation resumes but breathing does not or is inadequate, continue rescue breathing at 12–20 breaths/min.
 12. If adequate breathing and circulation resume, place the infant in the recovery position and monitor until help arrives.

♥ **Clinical Tip:** When you open an infant's airway by the head tilt–chin lift method, do not overextend the head or the airway will become obstructed.

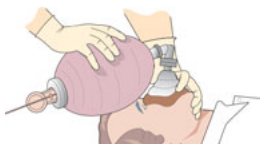CPR and Obstructed Airway Positions



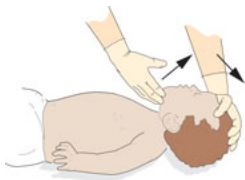
Head tilt–chin lift (adult or child)



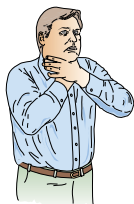Jaw thrust maneuver



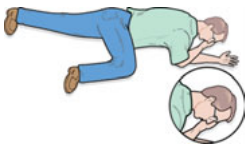Bag–valve–mask



Head tilt– chin lift (infant)



Universal choking sign



Recovery position

ACLS: Ventricular Fibrillation (VF) or Pulseless Ventricular Tachycardia (VT)

Clinical Presentation

- Unresponsive state
 - No respiration, pulse, or BP
1. Establish unresponsiveness with no respiration or pulse. Call for help.
 2. Begin CPR, provide oxygen, and attach an AED or monitor-defibrillator when available without interrupting CPR.
 3. When the device is attached, stop CPR and assess the rhythm. If shock is advised with use of an AED, defibrillate following AED prompts. If using a manual monitor-defibrillator, defibrillate at 120–200 J. If using a biphasic defibrillator, follow manufacturer's device-specific energy levels if known, or 200 J if unknown, or defibrillate at 360 J if using a monophasic defibrillator.
 4. Resume CPR. During CPR, establish IV/IO access. Prepare vaso-pressor dose (epinephrine or vasopressin).
 5. Assess the rhythm. If the rhythm is shockable, follow AED prompts or defibrillate at the same or higher energy for a biphasic manual defibrillator, or at 360 J for a monophasic manual defibrillator.
 6. Resume CPR; check the rhythm every 2 min (5 cycles of CPR).
 7. Insert an advanced airway (ET tube, LMA [laryngeal mask airway], or Combitube) if basic airway management is inadequate. Once an advanced airway is in place, compressions should be uninterrupted at 100/min and ventilations should be 8 to 10 breaths/min (1 breath every 6–8 sec).
 8. Administer epinephrine 1 mg (10 mL of 1:10,000) by the IV/IO method; follow with 20 mL IV flush. Repeat every 3–5 min; give 2.0–2.5 mg diluted in 10 mL normal saline if administering by ET tube; or administer a single dose of vasopressin 40 Units IV/IO to replace the first or second dose of epinephrine.
 9. Continue CPR; check the rhythm every 2 min.
 10. If the rhythm is still shockable, defibrillate as in step 5.
 11. Immediately resume CPR, beginning with compressions for another 2 min (5 cycles of CPR). Check the rhythm every 2 min.

ACLS: Pulseless Electrical Activity (PEA)

Clinical Presentation

- Unresponsive state
- No respiration, pulse, or BP
- Identifiable electrical rhythm on monitor but no pulse
 1. Establish unresponsiveness with no respiration or pulse. Call for help.
 2. Begin CPR, provide oxygen, and attach a manual monitor-defibrillator when available without interrupting CPR.
 3. When the device is attached, stop CPR to assess the rhythm. If an identifiable rhythm is noted on the monitor, immediately resume CPR beginning with compressions. Establish IV/IO access.
 4. During CPR, consider and treat possible causes:

<ul style="list-style-type: none"> ■ Trauma ■ Tension pneumothorax ■ Thrombosis (pulmonary or coronary) ■ Tamponade, cardiac ■ Toxins 	<ul style="list-style-type: none"> ■ Hypokalemia/hyperkalemia ■ Hypovolemia ■ Hypoxia ■ Hypoglycemia ■ Hypothermia ■ Hydrogen ion (acidosis)
--	--
 5. Continue CPR using five cycles of 30 compressions and 2 breaths; check the rhythm every 2 min.
 6. Insert an advanced airway (ET tube, LMA, or Combitube) if basic airway management is inadequate. Once an advanced airway is in place, compressions should be uninterrupted at 100/min and ventilations should be 8 to 10 breaths/min (1 breath every 6–8 sec).
 7. If PEA persists, administer epinephrine 1 mg IV/IO (10 mL of 1:10,000) and follow with 20 mL IV flush; repeat every 3–5 min; give 2.0–2.5 mg diluted in 10 mL normal saline if administering via ET tube; or administer a single dose of vasopressin 40 Units IV/IO to replace the first or second dose of epinephrine.
 8. Consider atropine 1 mg IV/IO if the heart rate on the ECG is less than 60 bpm. Repeat every 3–5 min as needed up to a total of 3 doses (3 mg).
 9. Continue CPR; check the rhythm every 2 min.
 10. If the rhythm is shockable with no pulse, follow VF/VT protocol (p 128).

ACLS: Asystole

Clinical Presentation

- Unresponsive state, no respiration, pulse, or BP
 - ECG shows flat line; no electrical activity
1. Establish unresponsiveness with no respiration or pulse. Call for help.
 2. Begin CPR, provide oxygen, and attach a manual monitor-defibrillator when available without interrupting CPR.
 3. When the device is attached, stop CPR to assess the rhythm. If no electrical activity (flat line or asystole) is noted on the monitor, immediately resume CPR beginning with compressions. Establish IV/IO access.
 4. During CPR, consider and treat possible causes:

■ Trauma	■ Hypokalemia/hyperkalemia
■ Tension pneumothorax	■ Hypovolemia
■ Thrombosis (pulmonary or coronary)	■ Hypoxia
■ Tamponade, cardiac	■ Hypoglycemia
■ Toxins	■ Hypothermia
	■ Hydrogen ion (acidosis)
 5. Continue CPR beginning with compressions and using five cycles of 30 compressions and 2 breaths; check the rhythm every 2 min.
 6. Insert an advanced airway (ET tube, LMA, or Combitube) if basic airway management is inadequate. Once an advanced airway is in place, compressions should be uninterrupted at 100/min and ventilations should be 8 to 10 breaths/min (1 breath every 6–8 sec).
 7. If asystole persists, administer epinephrine 1 mg IV/IO (10 mL of 1:10,000) and follow with 20 mL IV flush; repeat every 3–5 min; give 2.0–2.5 mg diluted in 10 mL normal saline if administering via ET tube; or administer a single dose of vasopressin 40 Units IV/IO to replace the first or second dose of epinephrine.
 8. Consider atropine 1 mg IV/IO if the ECG still shows asystole. Repeat every 3–5 min as needed up to a total of three doses (3 mg).
 9. Continue CPR; check the rhythm every 2 min.
 10. If the rhythm is shockable with no pulse, follow VF/VT protocol (p 128).
 11. If the rhythm is not shockable with no pulse, resume CPR and repeat steps 4–7.

ACLS: Acute Coronary Syndrome (ACS)

Clinical Presentation

- History of acute MI or angina
- Chest pain or discomfort
- Pain spreading to neck, shoulders, arms, or jaw
- Sudden unexplained shortness of breath, weakness, fatigue with or without chest pain/discomfort
- Associated nausea, diaphoresis, lightheadedness, fainting
 1. Establish responsiveness.
 2. Perform a primary ABCD survey.
 3. Measure vital signs, including oxygen saturation.
 4. Administer oxygen at 4 L/min, start an IV, and attach a cardiac monitor.
 5. Administer aspirin 160–325 mg orally (PO) if there is no history of aspirin allergy. Chewing the tablet is preferable; use non-enteric-coated tablets for the antiplatelet effect. Give within minutes of onset.
 6. Obtain a 12-lead ECG.
 7. If the 12-lead ECG shows ST segment elevation, notify the attending physician to begin the checklist for fibrinolytic therapy. If possible, prehospital providers should transport the patient to the closest facility with rapid coronary intervention capabilities.
 8. Administer nitroglycerin by the sublingual route 0.3–0.4 mg (1 tablet), repeated for a total of 3 doses at 5-min intervals for ongoing symptoms; or administer aerosol spray for 0.5–1.0 sec at 5-min intervals (provides 0.4 mg/dose), not to exceed 3 sprays in 15 min. Nitroglycerin administration requires a systolic BP greater than 90 mm Hg.
 9. Repeat nitroglycerin (see step 8) until chest pain is relieved, systolic BP falls below 90 mm Hg, or signs of ischemia or infarction are resolved.
 10. If chest pain is not relieved by nitroglycerin, administer morphine 2–4 mg IV (over 1–5 min). If symptoms are not resolved, administer 2–8 mg every 5–15 min if the patient is hemodynamically stable. Do not administer morphine if systolic BP is less than 90 mm Hg.

ACLS: Bradycardia

Clinical Presentation

- Pulse rate less than 60 bpm
- Sinus bradycardia, junctional escape rhythm, or AV block
- Symptoms of chest discomfort/pain, lightheadedness, dizziness
- Signs of hypotension, diaphoresis, altered mental status, CHF, shock
 1. Establish responsiveness.
 2. Perform a primary ABCD survey.
 3. Measure vital signs, including oxygen saturation.
 4. Supply oxygen, start an IV, and attach a cardiac monitor to identify the rhythm.
 5. Obtain a 12-lead ECG.
 6. If the patient is stable and asymptomatic with a heart rate less than 60 bpm, monitor and observe for any changes.
 7. If the patient is symptomatic with signs of poor perfusion, initiate treatment.
 8. In second-degree (Mobitz type II) or third-degree AV block, prepare for transcutaneous pacing.
 9. While awaiting the pacemaker, consider atropine 0.5 mg IV. May repeat every 3–5 min, maximum total dose 3 mg.
 10. If the patient fails to respond to atropine, sedate and begin transcutaneous pacing.
 11. If the patient is still hypotensive with severe bradycardia, or if pacing is unavailable or ineffective, consider epinephrine infusion, 2–10 mcg/min IV (add 1 mg of 1:1000 to 500 mL normal saline and infuse at 1–5 mL/min) or dopamine with continuous infusions (titrate to patient response) of 2–10 mcg/kg/min. Mix 400 mg/250 mL in normal saline, lactated Ringer's solution, or D5W (1600 mcg/mL).

♥ **Clinical Tip:** If the patient is symptomatic, do not delay transcutaneous pacing while waiting for atropine to take effect or for IV access.

♥ **Clinical Tip:** Use atropine with caution in a suspected acute MI; atropine may lead to rate-induced ischemia.

ACLS: Tachycardia—Unstable

Clinical Presentation

- Altered LOC
- Shortness of breath, diaphoresis, weakness, fatigue, syncope, chest discomfort or pain, palpitations
 1. Establish responsiveness.
 2. Perform a primary ABCD survey.
 3. Measure vital signs, including oxygen saturation.
 4. Supply oxygen, start an IV, and attach a cardiac monitor to identify the rhythm.
 5. Consider and treat possible causes:

■ Trauma	■ Hypokalemia/hyperkalemia
■ Tension pneumothorax	■ Hypovolemia
■ Thrombosis (pulmonary or coronary)	■ Hypoxia
■ Tamponade, cardiac	■ Hypoglycemia
■ Toxins	■ Hypothermia
	■ Hydrogen ion (acidosis)
 6. Establish that serious signs and symptoms are related to the tachycardia.
 7. If the patient is **unstable and symptomatic** with a heart rate greater than 150 bpm, prepare for immediate synchronized cardioversion. Patients with a healthy heart are unlikely to be unstable if the ventricular rate is less than 150 bpm; however, patients with cardiac disease may be unstable with heart rates less than 150 bpm. It is important to consider both patient stability and ECG as criteria for cardioversion.
 8. Premedicate with a sedative plus an analgesic whenever possible.
 9. Place the defibrillator in synchronized (Sync) mode.
 10. Administer synchronized cardioversion at a monophasic energy level of 100 J (or, if using a biphasic manual defibrillator, use the manufacturer's device-specific energy levels for synchronized cardioversion, usually 120–200 J). Reactivate the Sync mode before each attempted cardioversion.
 11. If there is no change, administer synchronized cardioversion at a monophasic energy level of 200 J (or the equivalent energy level for a biphasic manual defibrillator).

ACLS: Narrow-Complex Tachycardia—Stable Regular Rhythm

Clinical Presentation

- No serious signs or symptoms related to the tachycardia
- Regular ECG rhythm
- QRS narrow (<0.12 sec)
 1. Establish responsiveness.
 2. Perform a primary ABCD survey.
 3. Measure vital signs, including oxygen saturation.
 4. Supply oxygen, start an IV, and attach a cardiac monitor to identify the rhythm. Obtain a 12-lead ECG.
 5. Consider and treat possible causes:

<ul style="list-style-type: none"> ■ Trauma ■ Tension pneumothorax ■ Thrombosis (pulmonary or coronary) ■ Tamponade, cardiac ■ Toxins 	<ul style="list-style-type: none"> ■ Hypokalemia/hyperkalemia ■ Hypovolemia ■ Hypoxia ■ Hypoglycemia ■ Hypothermia ■ Hydrogen ion (acidosis)
--	--
 6. If the arrhythmia is PSVT (stable reentry SVT), attempt vagal maneuvers (carotid sinus massage if allowed or Valsalva maneuver).
 7. If the rhythm has not converted to sinus rhythm, administer adenosine 6 mg IV in the antecubital or another large vein rapidly over 1–3 sec, followed by a 20-mL bolus of normal saline, and elevate the arm immediately.
 8. If the rhythm has not converted in 1–2 min, repeat adenosine at 12 mg IV. If the rhythm still does not convert, a third dose of 12 mg IV may be given after another 1–2 min, maximum 30 mg.
 9. If the rhythm still does not convert, it may be atrial flutter, atrial tachycardia, or junctional tachycardia. Obtain expert consultation. Control the heart rate using diltiazem or beta blockers.
 10. If the rhythm converts, the arrhythmia was possibly PSVT (reentry SVT). Observe the patient and treat any recurrence with adenosine, diltiazem, or beta blockers. Obtain expert consultation.

♥ **Clinical Tip:** If the patient's condition becomes unstable during the tachycardia, perform immediate synchronized cardioversion.

ACLS: Narrow-Complex Tachycardia—Stable Irregular Rhythm

Clinical Presentation

- No serious signs or symptoms related to the tachycardia
- Irregular ECG rhythm
- QRS narrow (<0.12 sec)
 1. Establish responsiveness.
 2. Perform a primary ABCD survey.
 3. Measure vital signs, including oxygen saturation.
 4. Supply oxygen, start an IV, and attach a cardiac monitor to identify the rhythm. Obtain a 12-lead ECG.
 5. Consider and treat possible causes:

<ul style="list-style-type: none"> ■ Trauma ■ Tension pneumothorax ■ Thrombosis (pulmonary or coronary) ■ Tamponade, cardiac ■ Toxins 	<ul style="list-style-type: none"> ■ Hypokalemia/hyperkalemia ■ Hypovolemia ■ Hypoxia ■ Hypoglycemia ■ Hypothermia ■ Hydrogen ion (acidosis)
--	--
 6. Irregular rhythms (QRS <0.12 sec) are probably A-fib, A-flutter, or MAT. Consider expert consultation. Control the rate using diltiazem or beta blockers.
 7. If pulseless arrest develops, identify the arrhythmia and follow the algorithm for VF/VT (p 128), PEA (p 130), or asystole (p 132).

♥ **Clinical Tip:** If the patient's condition becomes unstable during the tachycardia, perform immediate synchronized cardioversion.

♥ **Clinical Tip:** Beta blockers should be used with caution in patients with pulmonary disease or CHF. Avoid in patients with bronchospastic disease.

ACLS: Wide-Complex Tachycardia—Stable Regular Rhythm

Clinical Presentation

- No serious signs and symptoms related to the tachycardia
- Regular ECG rhythm, QRS wide (>0.12 sec)
 1. Establish responsiveness.
 2. Perform a primary ABCD survey.
 3. Measure vital signs, including oxygen saturation.
 4. Supply oxygen, start an IV, and attach a cardiac monitor to identify the rhythm. Obtain a 12-lead ECG.
 5. Consider and treat possible causes:

<ul style="list-style-type: none"> ■ Trauma ■ Tension pneumothorax ■ Thrombosis (pulmonary or coronary) ■ Tamponade, cardiac ■ Toxins 	<ul style="list-style-type: none"> ■ Hypokalemia/hyperkalemia ■ Hypovolemia ■ Hypoxia ■ Hypoglycemia ■ Hypothermia ■ Hydrogen ion (acidosis)
--	--
 6. If the arrhythmia is monomorphic VT or an uncertain rhythm, consider expert consultation. Administer amiodarone 150 mg IV/IO over 10 min. Repeat as needed to a maximum dose of 2.2 g in 24 hr.
 7. If the rhythm still does not convert, prepare for cardioversion.
 8. Premedicate with a sedative plus an analgesic.
 9. Administer synchronized cardioversion incrementally as needed at monophasic energy levels of 100 J, 200 J, 300 J, and 360 J. If you are using biphasic equipment, the optimal initial dose is 100–120 J, with escalation as needed.
 10. If the rhythm still does not convert and the arrhythmia is SVT with aberrant conduction, administer adenosine 6 mg IV in the antecubital or another large vein rapidly over 1–3 sec, followed by a 20-mL bolus of normal saline, and elevate the arm immediately.
 11. If the rhythm does not convert and the arrhythmia is still SVT with aberrant conduction, wait 1–2 min, then give a second rapid dose of adenosine 12 mg IV. A third rapid dose of 12 mg IV may be given after another 1–2 min, maximum dose 30 mg.
 12. If pulseless arrest develops, identify the arrhythmia and follow the algorithm for VF/VT (p. 128).

ACLS: Wide-Complex Tachycardia—Stable Irregular Rhythm

Clinical Presentation

- No serious signs or symptoms related to the tachycardia
- Irregular rhythm
- QRS wide (>0.12 sec)
 1. Establish responsiveness.
 2. Perform a primary ABCD survey.
 3. Measure vital signs, including oxygen saturation.
 4. Supply oxygen, start an IV, and attach a cardiac monitor to identify the rhythm. Obtain a 12-lead ECG.
 5. Consider and treat possible causes:

<ul style="list-style-type: none"> ■ Trauma ■ Tension pneumothorax ■ Thrombosis (pulmonary or coronary) ■ Tamponade, cardiac ■ Toxins 	<ul style="list-style-type: none"> ■ Hypokalemia/hyperkalemia ■ Hypovolemia ■ Hypoxia ■ Hypoglycemia ■ Hypothermia ■ Hydrogen ion (acidosis)
--	--
 6. If the arrhythmia is A-fib with aberrant conduction, consider expert consultation. Control the rate using diltiazem or beta blockers.
 7. If the arrhythmia is pre-excited A-fib (A-fib with WPW Syndrome), seek expert consultation. Consider amiodarone, 150 mg IV/IO over 10 min. Avoid AV nodal blocking agents (e.g., adenosine, digoxin, diltiazem, verapamil).
 8. If the arrhythmia is recurrent polymorphic VT, seek expert consultation.
 9. If the arrhythmia is torsade de pointes, administer magnesium sulfate 1–2 g diluted in 50–100 mL of D5W IV/IO, given over 5–60 min, followed by an infusion at 0.5–1 g/hr titrated to control torsade de pointes.
 10. If pulseless arrest develops, identify the arrhythmia and follow the algorithm for VF/VT (p 128), PEA (p 130), or asystole (p 132).

♥ **Clinical Tip:** Monomorphic and polymorphic VT may rapidly deteriorate to VF.

ACLS: Stroke**Clinical Presentation**

- Facial droop, arm or leg weakness, abnormal speech
 - Confusion or coma
 - Headache, double vision, dizziness
1. Check for responsiveness. Support airway, breathing, and circulation.
 2. Give oxygen if needed.
 3. Perform a prehospital stroke assessment.
 4. Establish the time when the patient was last known to be normal.
 5. Transport; consider triage to a center with a stroke unit if appropriate.
 6. Alert the hospital. Be sure the hospital CT scan is functional.
 7. Check the patient's glucose level.

The following should be performed within the first 60 min after the patient has arrived at the emergency department.

Immediate general assessment and stabilization:

1. Assess airway, breathing, circulation, and vital signs.
2. Provide oxygen if the patient is hypoxic.
3. Obtain IV access and blood samples.
4. Check the glucose level; treat if indicated.
5. Perform a neurological screening assessment.
6. Activate the stroke team.
7. Order an emergent CT of the brain.
8. Obtain a 12-lead ECG.

Immediate neurological assessment by stroke team or designee:

1. Review the patient history.
2. Establish symptom onset.
3. Perform a neurological examination.
4. Interpret the CT scan.

Does the CT scan show hemorrhage? If yes, perform the following:

1. Check for any fibrinolytic contraindications.
2. Repeat the neurological examination.
3. Determine if the patient remains a candidate for fibrinolytic therapy.
4. If the patient is a candidate, give tPA; do not give anticoagulants or antiplatelet treatment for 24 hr.

ACLS: Stroke—cont'd

5. If the patient is not a candidate, administer aspirin; begin stroke pathway; initiate supportive therapy; treat comorbidities.

Does the CT scan show hemorrhage? If not, perform the following:

1. Consult a neurologist or neurosurgeon.
2. Administer aspirin; begin stroke pathway; initiate supportive therapy; treat comorbidities.

Stroke Assessment

Cincinnati Prehospital Stroke Scale

Facial Droop (have patient show teeth or smile)

- Normal—Both sides of face move equally well.
- Abnormal—One side of face does not move as well as the other side.

Arm Drift (have patient close eyes and hold both arms out)

- Normal—Both arms move the same or do not move at all.
- Abnormal—One arm does not move or drifts down lower than the other.

Speech (have the patient say, “You can’t teach an old dog new tricks.”)

- Normal—Patient uses correct words with no slurring.
- Abnormal—Patient slurs words, uses inappropriate words, or is unable to speak.

Note: The presence of a single abnormality has a sensitivity of 59% and a specificity of 89% when scored by prehospital providers.

Stroke Assessment—cont'd

Glasgow Coma Scale

Observation	Response	Score
Eye response	• Opens spontaneously	4
	• Opens to verbal commands	3
	• Opens to pain	2
	• No response	1
Best verbal response	• Alert and oriented	5
	• Disoriented but converses	4
	• Uses inappropriate words	3
	• Makes incomprehensible sounds	2
	• No response	1
Best motor response	• Reacts to verbal commands	6
	• Reacts to localized pain	5
	• Withdraws from pain	4
	• Abnormal flexion	3
	• Abnormal extension	2
	• No response	1
Total score		15

Score can range from 3 (lowest neurological function) to 15 (highest function).

Score 14–15: Mild dysfunction

Score 11–13: Moderate to severe dysfunction

Score 10: Severe dysfunction

PALS: Ventricular Fibrillation (VF) or Pulseless Ventricular Tachycardia (VT)

Clinical Presentation

- Pediatric patient
- Unresponsive state
- No respiration, pulse, or BP
 1. Establish unresponsiveness with no respiration or pulse. Call for help.
 2. Perform CPR for 2 min (5 cycles of CPR), provide oxygen, and attach an AED or monitor-defibrillator when available without interrupting CPR. Use pediatric pads or paddles.
 3. After 2 min of CPR, when the AED or monitor-defibrillator is attached, stop CPR and assess the rhythm. If shock is advised when using an AED, defibrillate following AED prompts. Defibrillate at 2 J/kg if using a manual biphasic or monophasic defibrillator.
 4. Resume CPR. During CPR, establish IV or IO access. Prepare a vasopressor dose (epinephrine).
 5. Assess the rhythm. If the rhythm is shockable, follow AED prompts or defibrillate at 4 J/kg if using a manual biphasic or monophasic defibrillator.
 6. Resume CPR, checking the rhythm every 2 min.
 7. Insert an advanced airway (ET tube) if basic airway management is inadequate. After an advanced airway is in place, compressions should be uninterrupted at 100/min and ventilations should be 8 to 10 breaths/min (1 breath every 6–8 sec).
 8. Administer epinephrine 0.01 mg/kg IV/IO (0.1 mL/kg of 1:10,000), repeating every 3–5 min. Give 0.1 mg/kg (0.1 mL/kg of 1:1,000) if administering by ET tube followed by 3–5 mL saline flush.
 9. Continue CPR; check the rhythm every 2 min.
 10. If the rhythm is still shockable, defibrillate as in step 5.
 11. Immediately resume CPR, beginning with compressions for another 5 cycles. Check the rhythm every 2 min.

Consider antiarrhythmics for shock-refractory VF or pulseless VT:

12. Administer amiodarone 5 mg/kg IV/IO, or lidocaine 1 mg/kg IV/IO.
13. If the arrhythmia is torsade de pointes, consider magnesium sulfate 25–50 mg/kg IV/IO (maximum dose 2 g) given over 10–20 min.

PALS: Pulseless Electrical Activity (PEA)

Clinical Presentation

- Pediatric patient
- Unresponsive state
- No respiration, pulse, or BP
- Identifiable electrical rhythm on monitor but no pulse
 1. Establish unresponsiveness with no respiration or pulse. Call for help.
 2. Begin CPR, provide oxygen, and attach a manual monitor-defibrillator if available without interrupting CPR.
 3. When the device is attached, stop CPR to assess the rhythm. If the monitor shows an identifiable rhythm with no pulse, immediately resume CPR beginning with compressions. Establish IV/IO access.
 4. During CPR, consider and treat possible causes:

<ul style="list-style-type: none"> ■ Trauma ■ Tension pneumothorax ■ Thrombosis (pulmonary or coronary) ■ Tamponade, cardiac ■ Toxins 	<ul style="list-style-type: none"> ■ Hypokalemia/hyperkalemia ■ Hypovolemia ■ Hypoxia ■ Hypoglycemia ■ Hypothermia ■ Hydrogen ion (acidosis)
--	--
 5. Continue CPR and check the rhythm every 2 min.
 6. Insert an advanced airway (ET tube) if basic airway management is inadequate. Once an advanced airway is in place, compressions should be uninterrupted at 100/min and ventilations should be 8 to 10 breaths/min (1 breath every 6–8 sec).
 7. If PEA persists, administer epinephrine 0.01 mg/kg IV/IO (0.1 mL/kg of 1:10,000); repeat every 3–5 min. Give 0.1 mg/kg (0.1 mL/kg of 1:1,000) if administering by ET tube followed by 3–5 mL saline flush.
 8. Continue CPR; check the rhythm every 2 min.
 9. If the rhythm is shockable with no pulse, follow VF/VT protocol (p 146).
 10. If the rhythm is not shockable with no pulse, resume CPR and repeat steps 4–8.
 11. If breathing and circulation are adequate and the ECG shows a stable rhythm, monitor and re-evaluate the patient.

♥ **Clinical Tip:** PEA may be caused by reversible conditions and can be treated if those conditions are quickly identified and corrected.

PALS: Asystole

Clinical Presentation

- Pediatric patient
- Unresponsive state, no respiration, pulse, or BP
- ECG shows flat line; no electrical activity
 1. Establish unresponsiveness with no respiration or pulse. Call for help.
 2. Begin CPR, provide oxygen, and attach manual monitor-defibrillator when available without interrupting CPR.
 3. When the device is attached, stop CPR to assess the rhythm. If the monitor shows no electrical activity (flat line or asystole), immediately resume CPR beginning with compressions. Establish IV/IO access.
 4. During CPR consider and treat possible causes:

<ul style="list-style-type: none"> ■ Trauma ■ Tension pneumothorax ■ Thrombosis (pulmonary or coronary) ■ Tamponade, cardiac ■ Toxins 	<ul style="list-style-type: none"> ■ Hypokalemia/hyperkalemia ■ Hypovolemia ■ Hypoxia ■ Hypoglycemia ■ Hypothermia ■ Hydrogen ion (acidosis)
--	--
 5. Continue CPR, checking the rhythm every 2 min.
 6. Insert an advanced airway (ET tube) if basic airway management is inadequate. Once an advanced airway is in place, compressions should be uninterrupted at 100/min and ventilations should be 8 to 10 breaths/min (1 breath every 6–8 sec).
 7. If asystole persists, administer epinephrine 0.01 mg/kg IV/IO (0.1 mL/kg of 1:10,000); repeat every 3–5 min. Give 0.1 mg/kg (0.1 mL/kg of 1:1,000) if administering by ET tube followed by 3–5 mL saline flush.
 8. Continue CPR; check the rhythm every 2 min.
 9. If the rhythm is shockable with no pulse, follow VF/VT protocol (p 146).
 10. If the rhythm is not shockable with no pulse, resume CPR and repeat steps 4–8.
 11. If asystole persists, consider whether proper resuscitation protocols were followed and reversible causes identified. If procedures were performed correctly, follow local criteria for terminating resuscitation efforts.

PALS: Bradycardia

Clinical Presentation

- Pediatric patient
- Pulse rate less than 60 bpm
- Respiratory distress or failure
- Signs of shock with hypotension, diaphoresis, altered mental status
 1. Establish responsiveness.
 2. Perform a primary ABCD survey.
 3. Measure vital signs, including oxygen saturation.
 4. Supply oxygen, start an IV, and attach cardiac monitor to identify rhythm.
 5. If the patient is stable and asymptomatic with a heart rate less than 60 bpm, monitor and observe for any changes.
 6. If the patient is symptomatic with a heart rate less than 60 bpm and signs of poor perfusion perform CPR.
 7. Consider and treat possible causes:

<ul style="list-style-type: none"> ■ Trauma ■ Tension pneumothorax ■ Thrombosis (pulmonary or coronary) ■ Tamponade, cardiac ■ Toxins 	<ul style="list-style-type: none"> ■ Hypokalemia/hyperkalemia ■ Hypovolemia ■ Hypoxia ■ Hypoglycemia ■ Hypothermia ■ Hydrogen ion (acidosis)
--	--
 8. If symptomatic bradycardia persists, administer epinephrine 0.01 mg/kg IV/IO (0.1 mL/kg of 1:10,000); repeat every 3–5 min. Give 0.1 mg/kg (0.1 mL/kg of 1:1,000) if administering by ET tube followed by 3–5 mL saline flush.
 9. For increased vagal tone or primary AV block, give a first dose of atropine 0.02 mg/kg IV/IO; may repeat every 3–5 min (minimum dose 0.1 mg, maximum total dose 1 mg).
 10. If the patient fails to respond to atropine, consider cardiac pacing.

PALS: Tachycardia—Unstable Narrow QRS (≤ 0.08 sec)

Clinical Presentation

- Pediatric patient
- Altered LOC
- Shortness of breath, diaphoresis, fatigue, syncope, poor perfusion
 1. Establish responsiveness.
 2. Perform a primary ABCD survey.
 3. Measure vital signs, including oxygen saturation.
 4. Supply oxygen, start an IV, and attach cardiac monitor to identify rhythm.
 5. Consider and treat possible causes:

<ul style="list-style-type: none"> ■ Trauma ■ Tension pneumothorax ■ Thrombosis (pulmonary or coronary) ■ Tamponade, cardiac ■ Toxins 	<ul style="list-style-type: none"> ■ Hypokalemia/hyperkalemia ■ Hypovolemia ■ Hypoxia ■ Hypoglycemia ■ Hypothermia ■ Hydrogen ion (acidosis)
--	--
 6. Establish that serious signs and symptoms are related to the tachycardia.
 7. If the patient is stable and asymptomatic, with a heart rate less than 180 bpm for a child and less than 220 bpm for an infant, the rhythm is probably sinus tachycardia. Search for and treat the underlying cause.
 8. If the heart rate is more than or equal to 180 bpm for a child and more than or equal to 220 bpm for an infant, the rhythm is probably SVT; consider vagal maneuvers.
 9. If IV access is available, give adenosine 0.1 mg/kg IV/IO rapid push (maximum first dose 6 mg), may double the first dose and give 0.2 mg/kg IV/IO rapid push (maximum second dose 12 mg).
 10. If IV access is available; apply cardioversion at 0.5–1.0 J/kg; if not effective, increase to 2 J/kg. Premedicate with a sedative plus an analgesic whenever possible but do not delay cardioversion.
 11. If cardioversion is unsuccessful seek expert consultation. Request either amiodarone 5 mg/kg IV/IO over 20–60 minutes *or* procainamide 15 mg/kg IV/IO over 30–60 minutes. **Do not routinely administer amiodarone and procainamide together.**

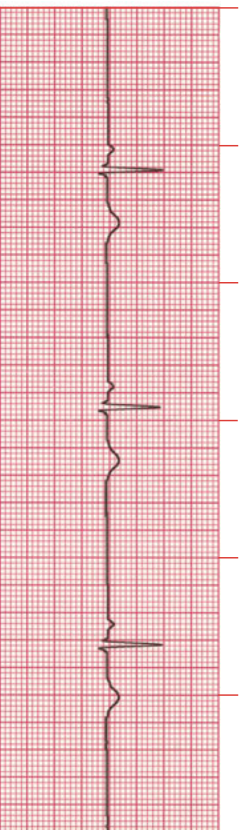
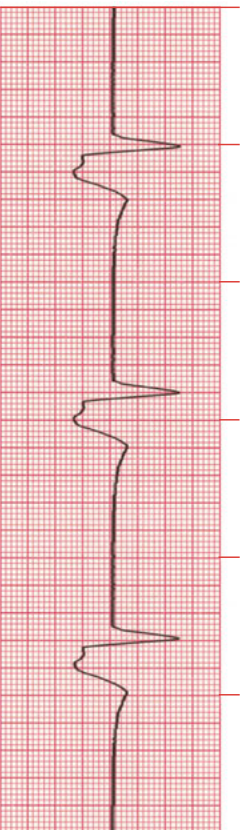
PALS: Tachycardia—Unstable Wide QRS (>0.08 sec)

Clinical Presentation

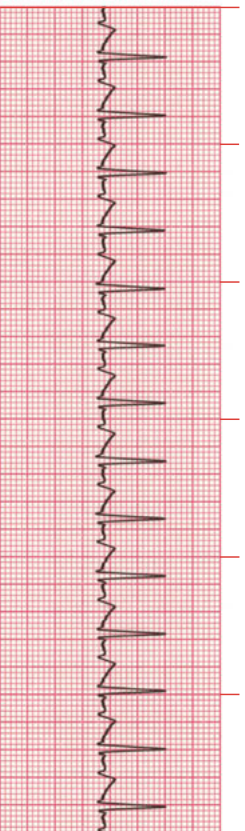
- Pediatric patient
- Altered LOC
- Shortness of breath, diaphoresis, fatigue, syncope, poor perfusion
 1. Establish responsiveness.
 2. Perform a primary ABCD survey.
 3. Measure vital signs, including oxygen saturation.
 4. Supply oxygen, start an IV, and attach cardiac monitor to identify rhythm.
 5. Consider and treat possible causes:

<ul style="list-style-type: none"> ■ Trauma ■ Tension pneumothorax ■ Thrombosis (pulmonary or coronary) ■ Tamponade, cardiac ■ Toxins 	<ul style="list-style-type: none"> ■ Hypokalemia/hyperkalemia ■ Hypovolemia ■ Hypoxia ■ Hypoglycemia ■ Hypothermia ■ Hydrogen ion (acidosis)
--	--
 6. Establish that serious signs and symptoms are related to the tachycardia.
 7. If the patient is unstable and symptomatic with a fast heart rate and wide QRS complex the rhythm is presumed to be ventricular tachycardia and cardioversion is indicated.
 8. Apply synchronized cardioversion at 0.5–1 J/kg; if not effective, increase to 2 J/kg. Premedicate with a sedative plus an analgesic whenever possible but do not delay cardioversion.
 9. May attempt adenosine if it does not delay electrical cardioversion. Give adenosine 0.1 mg/kg IV/IO rapid push (maximum first dose 6 mg), may double the first dose and give 0.2 mg/kg IV/IO rapid push (maximum second dose 12 mg).
 10. If cardioversion is unsuccessful, seek expert consultation. Request either amiodarone 5 mg/kg IV/IO over 20–60 minutes *or* procainamide 15 mg/kg IV/IO over 30–60 minutes. **Do not routinely administer amiodarone and procainamide together.**

♥ **Clinical Tip:** Wide-complex tachycardia is a relatively uncommon rhythm in children, however it can be seen in children with heart disease, drug ingestions (tricyclic antidepressants), and hyperkalemia.

ECG Test Strip 1**Note:** All ECG strips in Tab 9 were recorded in Lead II.**ECG Test Strip 2**

ECG Test Strip 3



153

ECG Strip 1	ECG Strip 2	ECG Strip 3
Rate:	Rate:	Rate:
Rhythm:	Rhythm:	Rhythm:
P Waves:	P Waves:	P Waves:
PR Interval:	PR Interval:	PR Interval:
QRS:	QRS:	QRS:
Interpretation:	Interpretation:	Interpretation:

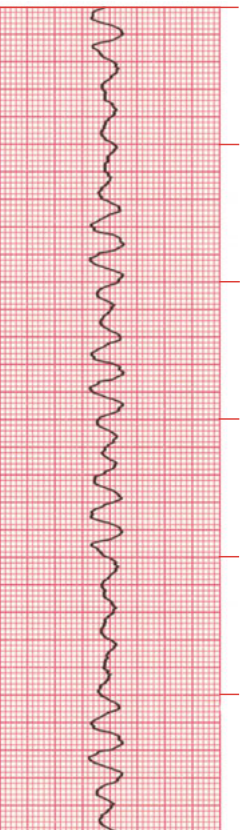
Case Study One: A 66-year-old woman with a history of heart disease is found unresponsive. This is an unwitnessed cardiac arrest with the initial rhythm shown in ECG strip 4. CPR is initiated while the defibrillator is charged. Strip 5 shows the rhythm following defibrillation. Because the first defibrillation was unsuccessful, the machine is charged a second time. The next rhythm is shown in strip 6.

ECG Strip 4 Interpretation:

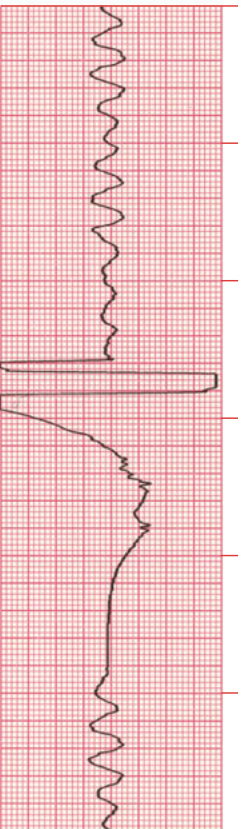
ECG Strip 5 Interpretation:

ECG Strip 6 Interpretation:

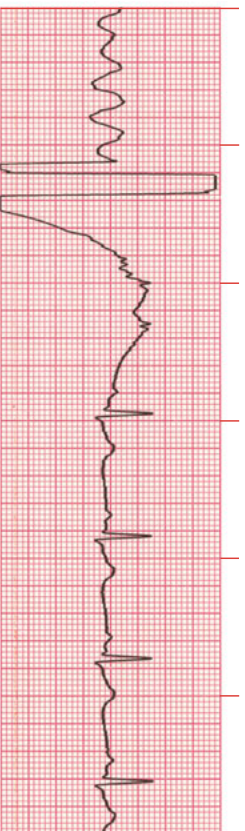
ECG Test Strip 4



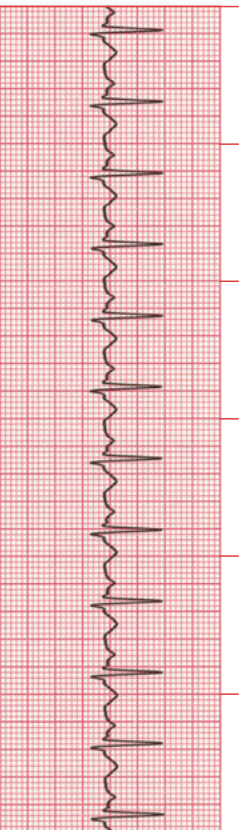
ECG Test Strip 5



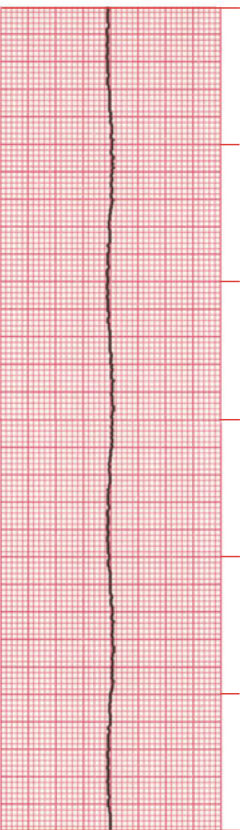
15 ECG Test Strip 6



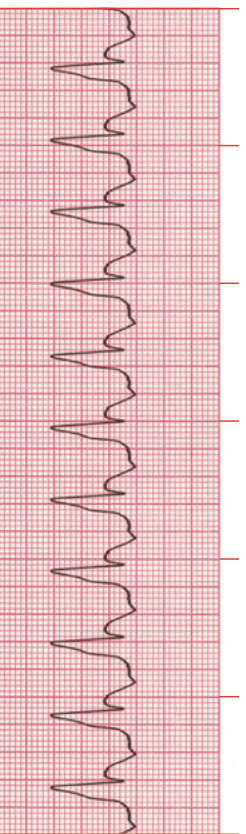
ECG Test Strip 7



ECG Test Strip 8



ECG Test Strip 9



157

ECG Strip 7	ECG Strip 8	ECG Strip 9
Rate:	Rate:	Rate:
Rhythm:	Rhythm:	Rhythm:
P Waves:	P Waves:	P Waves:
PR Interval:	PR Interval:	PR Interval:
QRS:	QRS:	QRS:
Interpretation:	Interpretation:	Interpretation:

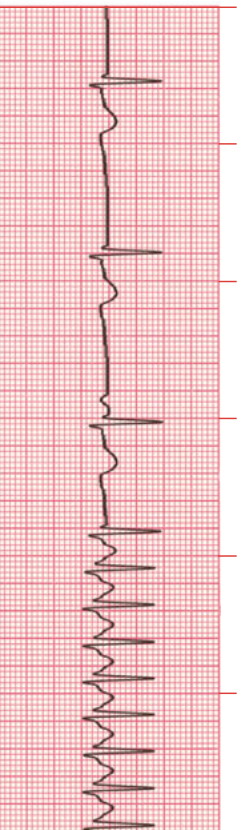
Case Study Two: A 72-year-old man is complaining of dizziness and anxiety. Strip 10 shows his initial rhythm. An IV is started and the patient is given oxygen, but his vital signs become unstable (strip 11). An IVP of adenosine is given and his condition stabilizes with the final rhythm, shown in strip 12.

ECG Strip 10 Interpretation:

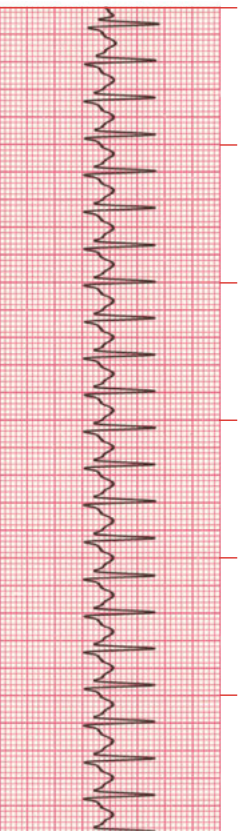
ECG Strip 11 Interpretation:

ECG Strip 12 Interpretation:

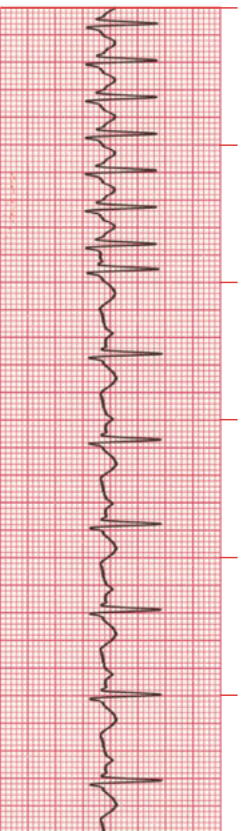
ECG Test Strip 10



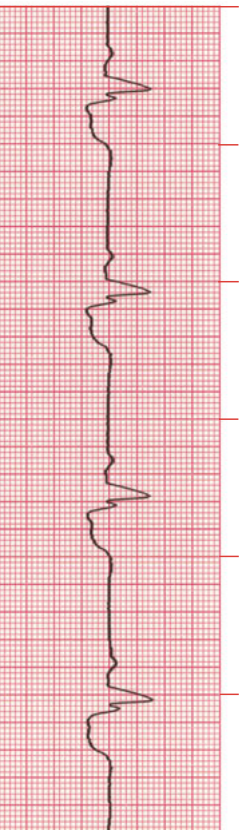
ECG Test Strip 11



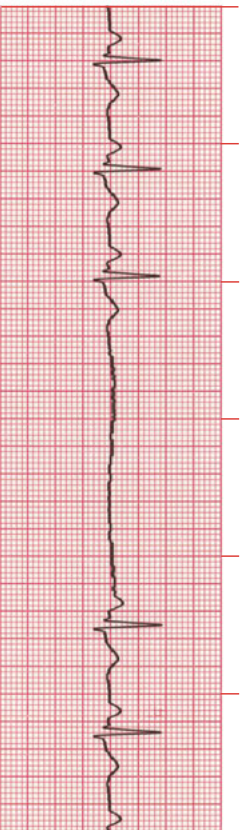
159 ECG Test Strip 12



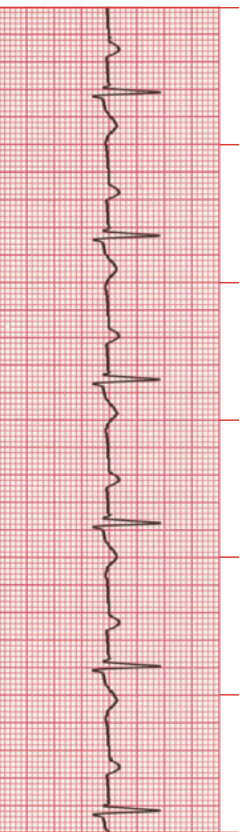
ECG Test Strip 13



ECG Test Strip 14



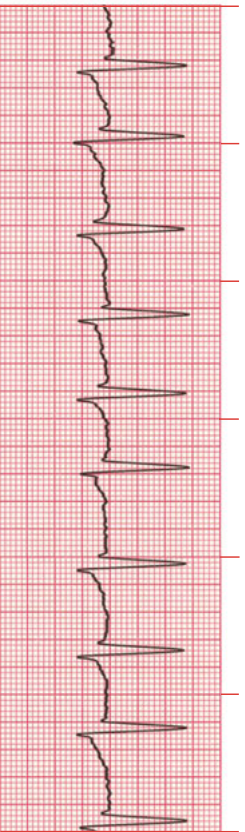
ECG Test Strip 15



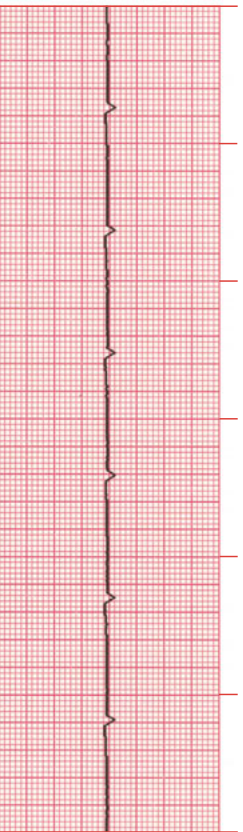
161

ECG Strip 13	ECG Strip 14	ECG Strip 15
Rate:	Rate:	Rate:
Rhythm:	Rhythm:	Rhythm:
P Waves:	P Waves:	P Waves:
PR Interval:	PR Interval:	PR Interval:
QRS:	QRS:	QRS:
Interpretation:	Interpretation:	Interpretation:

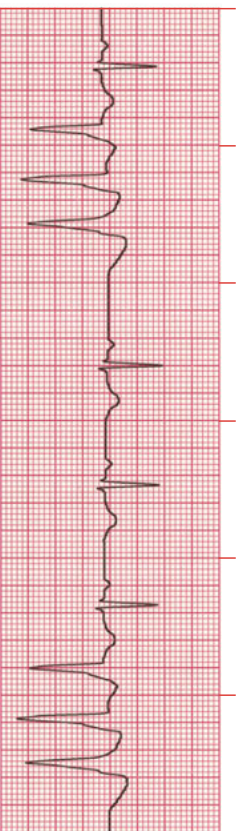
ECG Test Strip 16



ECG Test Strip 17



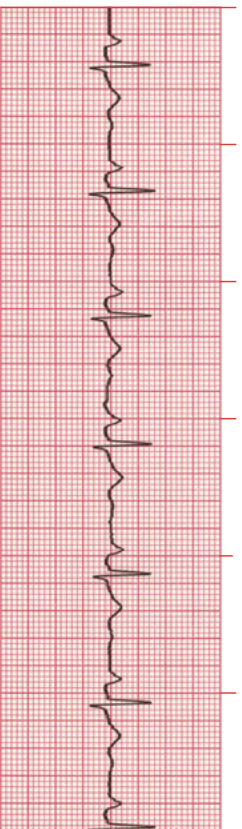ECG Test Strip 18



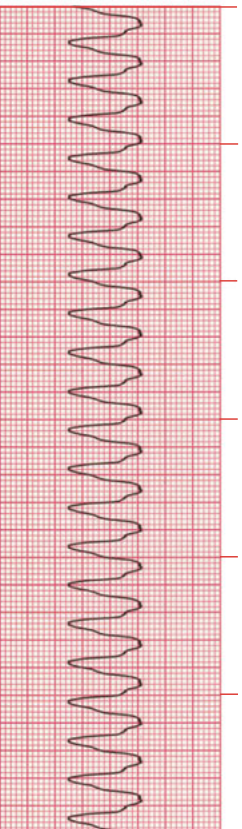
163

ECG Strip 16	ECG Strip 17	ECG Strip 18
Rate:	Rate:	Rate:
Rhythm:	Rhythm:	Rhythm:
P Waves:	P Waves:	P Waves:
PR Interval:	PR Interval:	PR Interval:
QRS:	QRS:	QRS:
Interpretation:	Interpretation:	Interpretation:

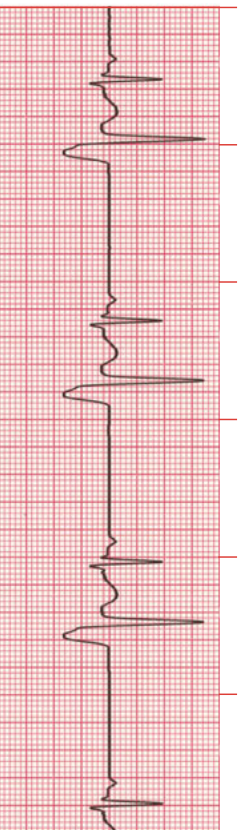
ECG Test Strip 19



ECG Test Strip 20



ECG Test Strip 21



165

ECG Strip 19		ECG Strip 20		ECG Strip 21	
Rate:		Rate:		Rate:	
Rhythm:		Rhythm:		Rhythm:	
P Waves:		P Waves:		P Waves:	
PR Interval:		PR Interval:		PR Interval:	
QRS:		QRS:		QRS:	
Interpretation:		Interpretation:		Interpretation:	

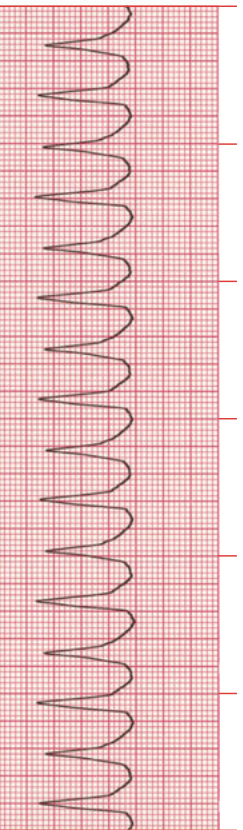
Case Study Three: A 44-year-old man complains of severe chest pain. He has diaphoresis, a BP of 80/60, and 24 respirations per min. The initial rhythm, recorded by the paramedics, is shown in strip 22. An IV is started and the patient is given oxygen. Because his condition is unstable, he receives sedation and cardioversion (strip 23). There is no change, and cardioversion is performed a second time (strip 24).

ECG Strip 22 Interpretation:

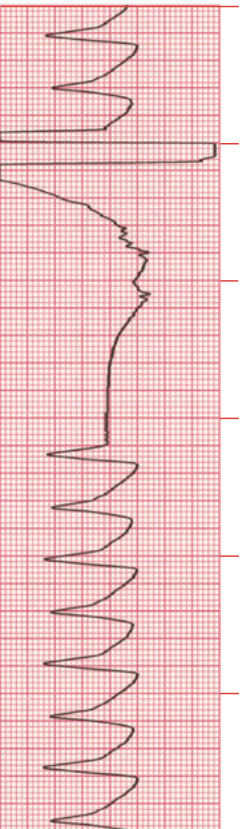
ECG Strip 23 Interpretation:

ECG Strip 24 Interpretation:

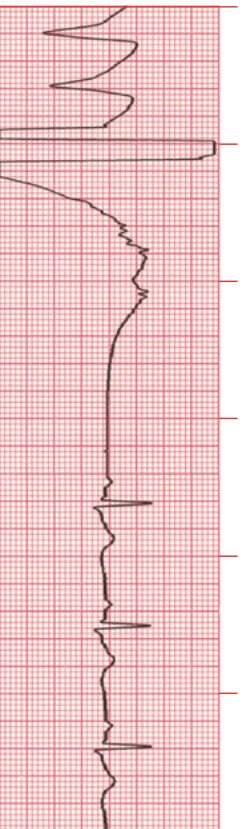
ECG Test Strip 22



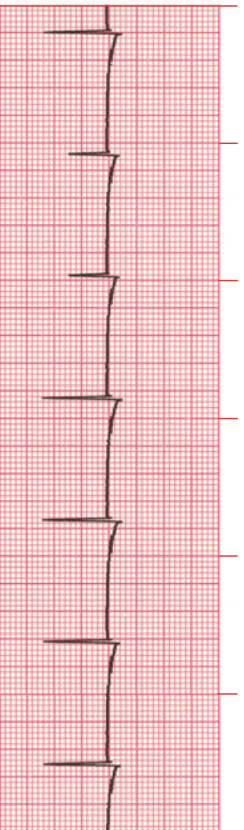
ECG Test Strip 23



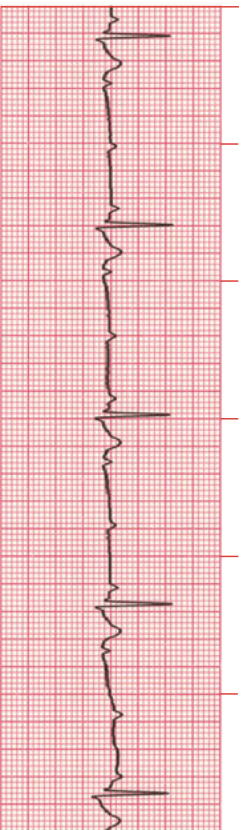167 ECG Test Strip 24



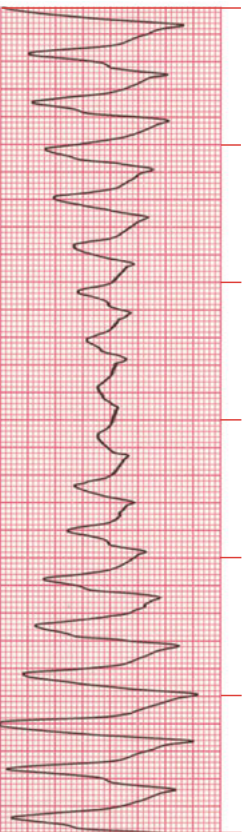
ECG Test Strip 25



ECG Test Strip 26



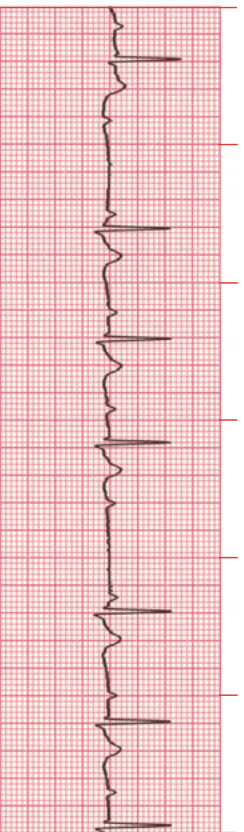
ECG Test Strip 27



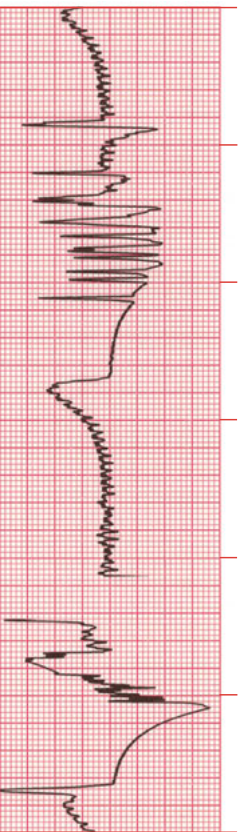
169

ECG Strip 25	ECG Strip 26	ECG Strip 27
Rate:	Rate:	Rate:
Rhythm:	Rhythm:	Rhythm:
P Waves:	P Waves:	P Waves:
PR Interval:	PR Interval:	PR Interval:
QRS:	QRS:	QRS:
Interpretation:	Interpretation:	Interpretation:

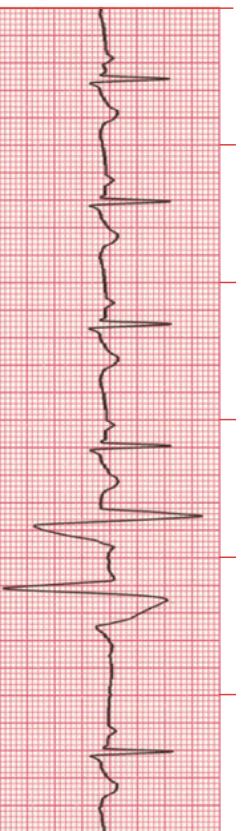
ECG Test Strip 28



ECG Test Strip 29



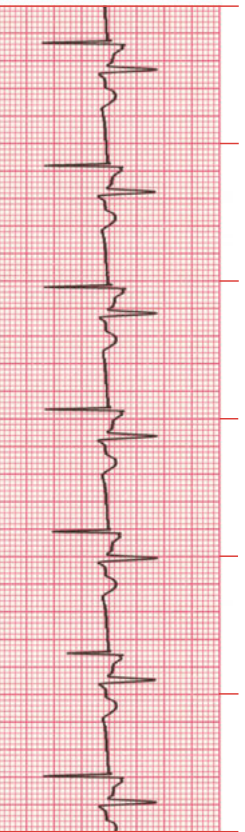
ECG Test Strip 30



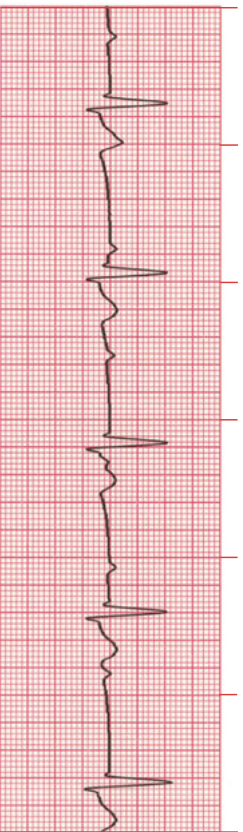
171

ECG Strip 28		ECG Strip 29		ECG Strip 30	
Rate:		Rate:		Rate:	
Rhythm:		Rhythm:		Rhythm:	
P Waves:		P Waves:		P Waves:	
PR Interval:		PR Interval:		PR Interval:	
QRS:		QRS:		QRS:	
Interpretation:		Interpretation:		Interpretation:	

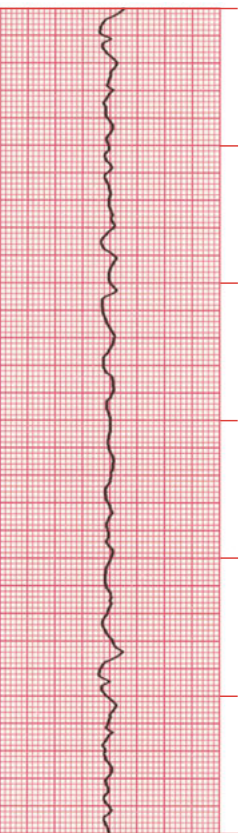
ECG Test Strip 31



ECG Test Strip 32



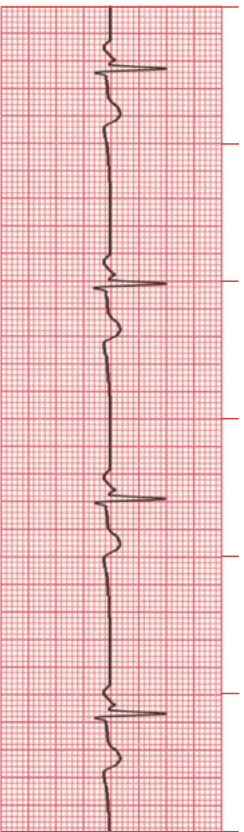
ECG Test Strip 33



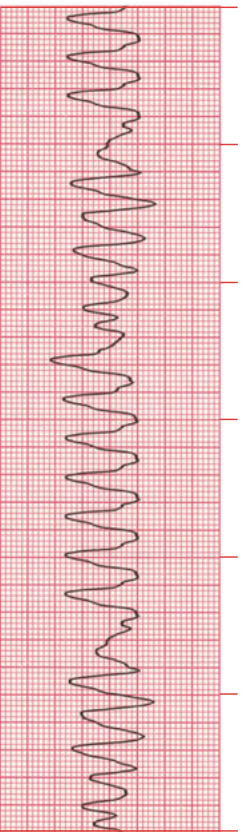
173

ECG Strip 31	ECG Strip 32	ECG Strip 33
Rate:	Rate:	Rate:
Rhythm:	Rhythm:	Rhythm:
P Waves:	P Waves:	P Waves:
PR Interval:	PR Interval:	PR Interval:
QRS:	QRS:	QRS:
Interpretation:	Interpretation:	Interpretation:

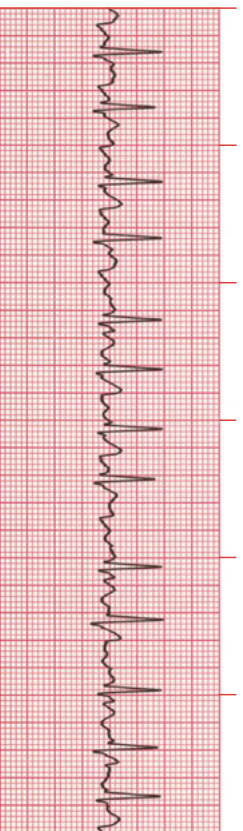
ECG Test Strip 34



ECG Test Strip 35



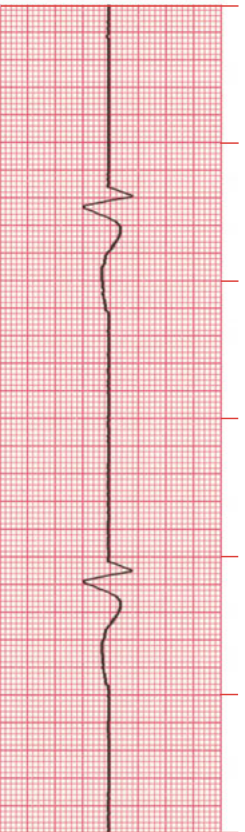
ECG Test Strip 36



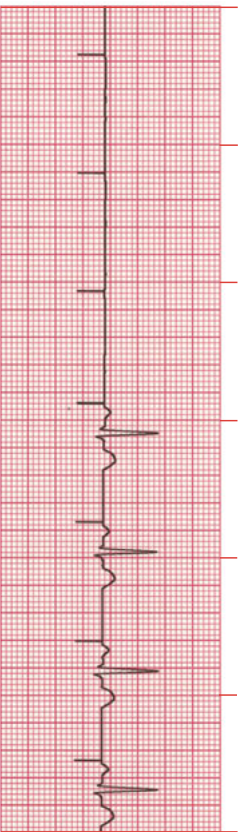
175

ECG Strip 34	ECG Strip 35	ECG Strip 36
Rate:	Rate:	Rate:
Rhythm:	Rhythm:	Rhythm:
P Waves:	P Waves:	P Waves:
PR Interval:	PR Interval:	PR Interval:
QRS:	QRS:	QRS:
Interpretation:	Interpretation:	Interpretation:

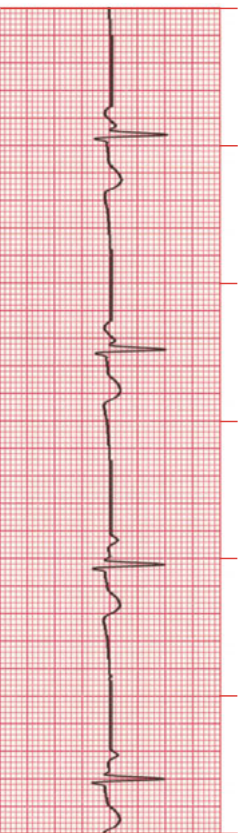
ECG Test Strip 37



ECG Test Strip 38



ECG Test Strip 39



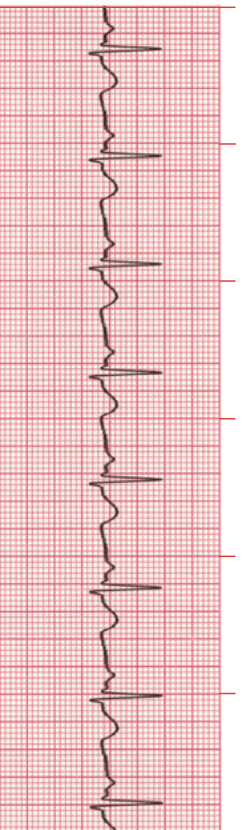
177

ECG Strip 37 Interpretation:

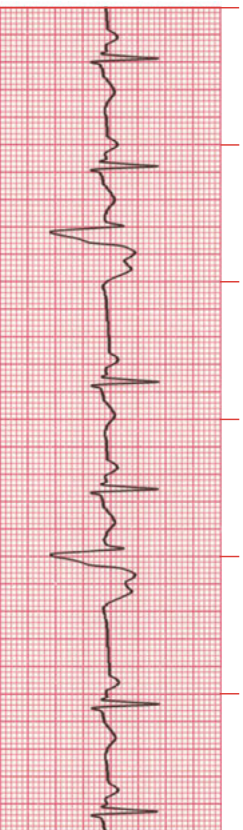
ECG Strip 38 Interpretation:

ECG Strip 39 Interpretation:

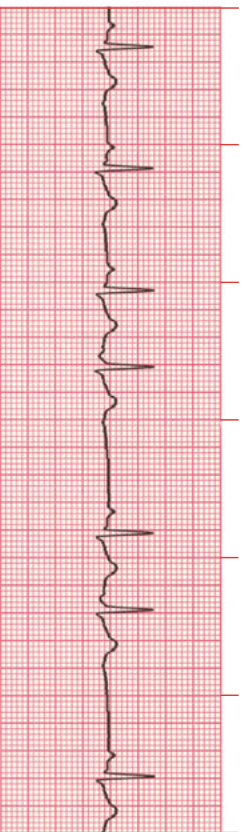
ECG Test Strip 40



ECG Test Strip 41



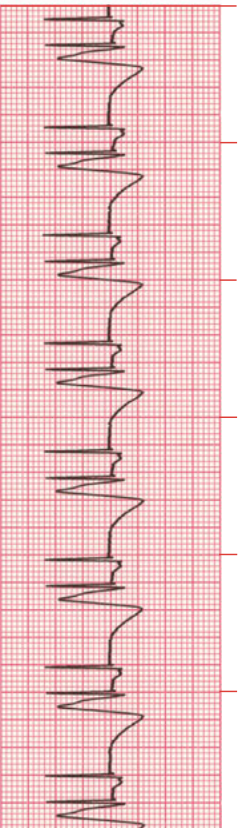ECG Test Strip 42



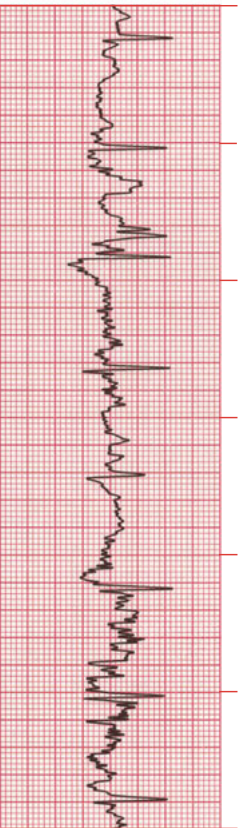
179

ECG Strip 40		ECG Strip 41		ECG Strip 42	
Rate:		Rate:		Rate:	
Rhythm:		Rhythm:		Rhythm:	
P Waves:		P Waves:		P Waves:	
PR Interval:		PR Interval:		PR Interval:	
QRS:		QRS:		QRS:	
Interpretation:		Interpretation:		Interpretation:	

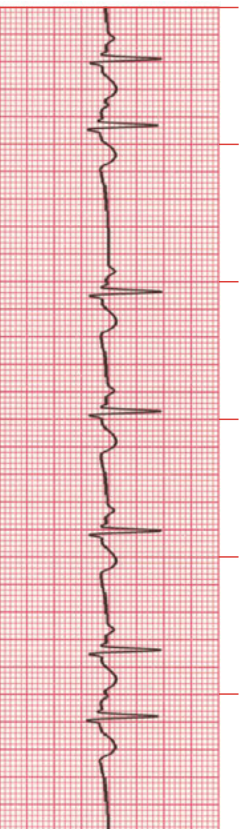
ECG Test Strip 43



ECG Test Strip 44



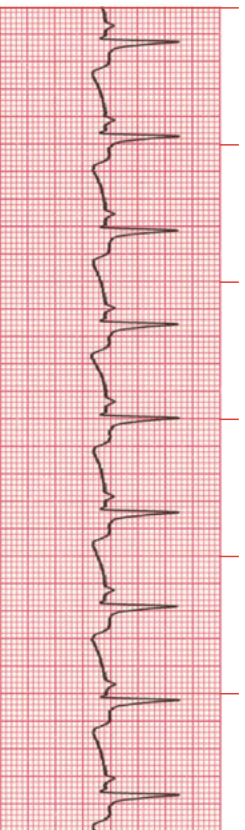
ECG Test Strip 45



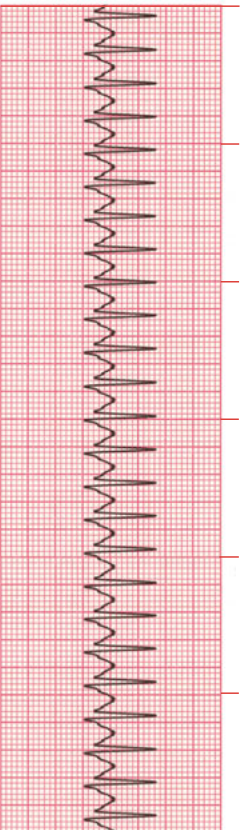
181

ECG Strip 43	ECG Strip 44	ECG Strip 45
Rate:	Rate:	Rate:
Rhythm:	Rhythm:	Rhythm:
P Waves:	P Waves:	P Waves:
PR Interval:	PR Interval:	PR Interval:
QRS:	QRS:	QRS:
Interpretation:	Interpretation:	Interpretation:

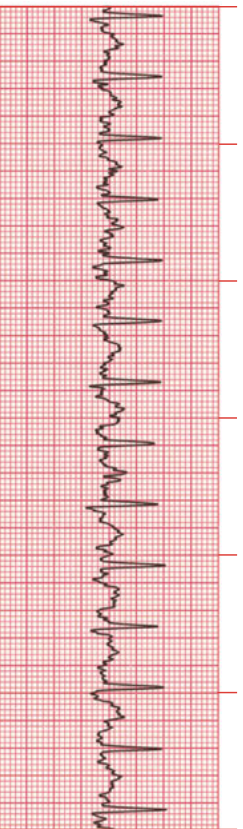ECG Test Strip 46



ECG Test Strip 47



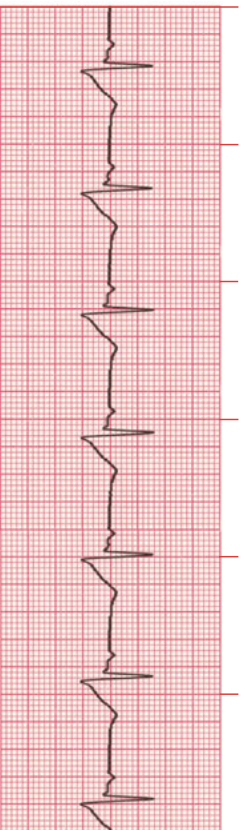
ECG Test Strip 48



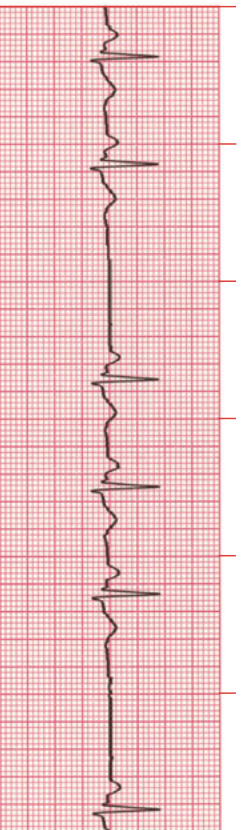
183

ECG Strip 46	ECG Strip 47	ECG Strip 48
Rate:	Rate:	Rate:
Rhythm:	Rhythm:	Rhythm:
P Waves:	P Waves:	P Waves:
PR Interval:	PR Interval:	PR Interval:
QRS:	QRS:	QRS:
Interpretation:	Interpretation:	Interpretation:

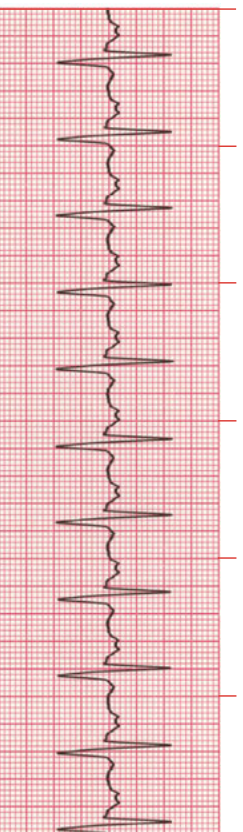ECG Test Strip 49



ECG Test Strip 50



ECG Test Strip 51



185

ECG Strip 49		ECG Strip 50		ECG Strip 51	
Rate:		Rate:		Rate:	
Rhythm:		Rhythm:		Rhythm:	
P Waves:		P Waves:		P Waves:	
PR Interval:		PR Interval:		PR Interval:	
QRS:		QRS:		QRS:	
Interpretation:		Interpretation:		Interpretation:	

Answers to ECG Test Strips

ECG Strip 1	ECG Strip 2	ECG Strip 3
Rate: 35 bpm	Rate: 34 bpm	Rate: Ventricular 150 bpm, atrial 280 bpm
Rhythm: Regular	Rhythm: Regular	Rhythm: Regular
P Waves: Normal	P Waves: None	P Waves: Flutter waves
PR Interval: 0.16 sec	PR Interval: None	PR Interval: Variable
QRS: 0.10 sec	QRS: 0.20 sec	QRS: 0.08 sec
Interpretation: Sinus bradycardia	Interpretation: Idioventricular rhythm	Interpretation: Atrial flutter with 2:1 conduction

ECG Strip 4 Interpretation: Ventricular fibrillation
ECG Strip 5 Interpretation: VF with defibrillation converting back to same rhythm
ECG Strip 6 Interpretation: VF with defibrillation converting to sinus rhythm at 68 bpm

ECG Strip 7	ECG Strip 8	ECG Strip 9
Rate: 115 bpm	Rate: None	Rate: 115 bpm
Rhythm: Regular	Rhythm: None	Rhythm: Regular
P Waves: Normal	P Waves: None	P Waves: None
PR Interval: 0.12 sec	PR Interval: None	PR Interval: None
QRS: 0.10 sec	QRS: None	QRS: Wide (>0.12 sec), bizarre
Interpretation: Sinus tachycardia	Interpretation: Asystole	Interpretation: Ventricular tachycardia—monomorphic

ECG Strip 10 Interpretation: Paroxysmal supraventricular tachycardia—initial junctional rhythm at 48 bpm converting to supraventricular tachycardia at 250 bpm

ECG Strip 11 Interpretation: SVT at 250 bpm

ECG Strip 12 Interpretation: SVT at 250 bpm converting to a sinus rhythm at 100 bpm

187

ECG Strip 13	ECG Strip 14	ECG Strip 15
Rate: 41 bpm	Rate: Basic rate 79 bpm	Rate: 58 bpm
Rhythm: Regular	Rhythm: Irregular	Rhythm: Regular
P Waves: Normal	P Waves: Normal	P Waves: Normal
PR Interval: 0.20 sec	PR Interval: 0.16 sec	PR Interval: 0.32 sec
QRS: 0.24 sec	QRS: 0.08 sec	QRS: 0.08 sec
Interpretation: Sinus bradycardia with a bundle branch block	Interpretation: Sinus rhythm with sinus pause/arrest	Interpretation: Sinus bradycardia with first-degree AV block

ECG Strip 16	ECG Strip 17	ECG Strip 18
Rate: Atrial >350 bpm, ventricular 88–115 bpm	Rate: Atrial 60 bpm	Rate: Basic rate 68 bpm
Rhythm: Irregular	Rhythm: Atrial regular	Rhythm: Irregular
P Waves: None	P Waves: Normal	P Waves: Normal
PR Interval: None	PR Interval: None	PR Interval: 0.16 sec
QRS: 0.12 sec	QRS: None	QRS: 0.08 sec
Interpretation: Atrial fibrillation	Interpretation: P Wave asystole	Interpretation: Sinus rhythm with premature ventricular contractions—triplets

ECG Strip 19	ECG Strip 20	ECG Strip 21
Rate: 65 bpm	Rate: 214 bpm	Rate: Basic rate 35 bpm
Rhythm: Regular	Rhythm: Regular	Rhythm: Regular
P Waves: Normal	P Waves: None	P Waves: Normal
PR Interval: 0.20 sec	PR Interval: None	PR Interval: 0.16 sec
QRS: 0.08 sec	QRS: Wide (>0.12 sec), bizarre	QRS: 0.08 sec
Interpretation: Normal sinus rhythm with U wave	Interpretation: VT—monomorphic	Interpretation: Sinus bradycardia with ventricular bigeminy

ECG Strip 22 Interpretation: VT—monomorphic
ECG Strip 23 Interpretation: VT—monomorphic with cardioversion converting to same rhythm
ECG Strip 24 Interpretation: VT—monomorphic with cardioversion converting to a sinus rhythm at 65 bpm

ECG Strip 25	ECG Strip 26	ECG Strip 27
Rate: Pacing spikes 68 bpm	Rate: Atrial 125 bpm, ventricular 44 bpm	Rate: 200–250 bpm
Rhythm: Regular pacing spikes	Rhythm: Regular	Rhythm: Irregular
P Waves: None	P Waves: Normal	P Waves: None
PR Interval: None	PR Interval: 0.16 sec	PR Interval: None
QRS: None	QRS: 0.10 sec	QRS: Wide (>0.12 sec), bizarre
Interpretation: Pacemaker—100% failure to capture, underlying rhythm asystole	Interpretation: Second-degree AV block Type II with 3:1 conduction	Interpretation: VT—torsade de pointes

ECG Strip 28	ECG Strip 29	ECG Strip 30
Rate: 50–75 bpm	Rate: None	Rate: Basic rate 68 bpm
Rhythm: Irregular	Rhythm: None	Rhythm: Irregular
P Waves: Normal	P Waves: None	P Waves: Normal
PR Interval: 0.12–0.28 sec	PR Interval: None	PR Interval: 0.16 sec
QRS: 0.08 sec	QRS: None	QRS: 0.10 sec
Interpretation: Second-degree AV block Type I	Interpretation: Loose electrodes	Interpretation: Sinus rhythm with multiform PVCs—couplets

ECG Strip 31	ECG Strip 32	ECG Strip 33
Rate: 68 bpm	Rate: Atrial 75 bpm, ventricular 48 bpm	Rate: Indeterminate
Rhythm: Regular	Rhythm: Regular	Rhythm: Irregular
P Waves: Upright with pacing spikes	P Waves: Normal, superimposed on QRS and T waves	P Waves: None
PR Interval: 0.16 sec	PR Interval: Varies	PR Interval: None
QRS: 0.10 sec	QRS: 0.16 sec	QRS: None
Interpretation: Atrial pacemaker with 100% capture	Interpretation: Third-degree AV block	Interpretation: VF

ECG Strip 34	ECG Strip 35	ECG Strip 36
Rate: 48 bpm	Rate: 250 bpm	Rate: Atrial ≥ 350 bpm, ventricular 94–167 bpm
Rhythm: Regular	Rhythm: Irregular	Rhythm: Irregular
P Waves: Inverted	P Waves: None	P Waves: None
PR Interval: 0.12 sec	PR Interval: None	PR Interval: None
QRS: 0.08 sec	QRS: Wide (>0.12 sec), bizarre	QRS: 0.10 sec
Interpretation: Junctional rhythm	Interpretation: VT—polymorphic	Interpretation: A-fib

ECG Strip 37 Interpretation: Agonal rhythm at 22 bpm

ECG Strip 38 Interpretation: Pacemaker failure to capture. When the pacemaker voltage is increased there is capture at pacemaker spike 4.

ECG Strip 39 Interpretation: Junctional bradycardia at 38 bpm converting to sinus bradycardia at 38 bpm

ECG Strip 40	ECG Strip 41	ECG Strip 42
Rate: 75 bpm	Rate: Basic rate 79 bpm	Rate: Basic rate 68 bpm
Rhythm: Regular	Rhythm: Irregular	Rhythm: Irregular
P Waves: Normal	P Waves: Normal	P Waves: Normal; none associated with premature junctional contraction
PR Interval: 0.16 sec	PR Interval: 0.20 sec	PR Interval: 0.16 sec
QRS: 0.08 sec	QRS: 0.10 sec	QRS: 0.10 sec
Interpretation: Normal sinus rhythm	Interpretation: Sinus rhythm with ventricular trigeminy	Interpretation: Sinus rhythm with PJs at beats 4 and 6

ECG Strip 43	ECG Strip 44	ECG Strip 45
Rate: 75 bpm	Rate: 75 bpm	Rate: 68 bpm
Rhythm: Regular	Rhythm: Regular	Rhythm: Irregular
P Waves: Upright with pacing spike	P Waves: Not visible	P Waves: Normal
PR Interval: 0.20 sec	PR Interval: Not measurable	PR Interval: 0.16 sec
QRS: 0.16 sec	QRS: Not measurable	QRS: 0.10 sec
Interpretation: Atrial-ventricular pacemaker	Interpretation: Sinus rhythm with muscle artifact	Interpretation: Sinus rhythm with two premature atrial contractions (beats 2 and 7)

191

ECG Strip 46	ECG Strip 47	ECG Strip 48
Rate: 88 bpm	Rate: 250 bpm	Rate: 136 bpm
Rhythm: Regular	Rhythm: Regular	Rhythm: Regular
P Waves: Normal	P Waves: Buried in T waves	P Waves: Not visible
PR Interval: 0.12 sec	PR Interval: Not measurable	PR Interval: Not measurable
QRS: 0.12 sec	QRS: 0.08 sec	QRS: 0.10 sec
Interpretation: Sinus rhythm with ST segment elevation	Interpretation: SVT	Interpretation: Sinus tachycardia with muscle artifact

ECG Strip 49	ECG Strip 50	ECG Strip 51
Rate: 71 bpm	Rate: Basic rate 79 bpm	Rate: 107 bpm
Rhythm: Regular	Rhythm: Irregular	Rhythm: Regular
P Waves: Normal	P Waves: Normal	P Waves: Notched (P prime)
PR Interval: 0.16 sec	PR Interval: 0.16 sec	PR Interval: 0.20 sec
QRS: 0.10 sec	QRS: 0.10 sec	QRS: 0.12 sec
Interpretation: Sinus rhythm with ST segment depression	Interpretation: Sinus rhythm with two SA blocks	Interpretation: Sinus tachycardia with P prime wave

Troubleshooting ECG Problems

Without proper assessment and treatment, a patient with an abnormal ECG could have a potentially fatal outcome. An accurate and properly monitored ECG is extremely important, so remember the following troubleshooting tips:

- Place leads in the correct position. Incorrect placement can give false readings.
- Avoid placing leads over bony areas.
- In patients with large breasts, place the electrodes under the breast. The most accurate tracings are obtained through the smallest amount of fat tissue.
- Apply tincture of benzoin to the electrode sites if the patient is diaphoretic. The electrodes will adhere to the skin better.
- Shave hair at the electrode site if it interferes with contact between the electrode and the skin.
- Discard old electrodes and use new ones if the gel on the back of the electrode dries.

Cable Connections

- It is important to know if you are using an American or a European cable for ECG monitoring. The colors of the wires differ as shown below.

Monitoring Cable Connections

U.S.	Connect to	Europe
White	Right arm	Red
Black	Left arm	Yellow
Red	Left leg	Green
Green	Right leg	Black
Brown	Chest	White

Patient Cable

- Monitoring cables contain varying numbers of wires.
- 3- and 4-wire cables: Allow a choice of limb and augmented leads.
- 5-wire cable: Allows a choice of limb and augmented leads plus a chest lead.
- 10-wire cable: Records a 12-lead ECG.

Patient ECG Record

Patient Name: _____

Sex : Female Male

Heart Rate: _____ bpm

- Normal (60–100 bpm) Y N
- Bradycardia (<60 bpm) Y N
- Tachycardia (>100 bpm) Y N

Rhythm

- Regular Y N
- Irregular Y N
- P waves Y N

P waves

- Normal (upright and uniform) Y N
- Inverted Y N
- P wave associated with QRS complex Y N
- PR interval normal (0.12–0.20 sec) Y N
- P waves and QRS complexes associated with one another Y N

QRS complex

- Normal (0.06–0.10 sec) Y N
- Wide (>0.10 sec) Y N

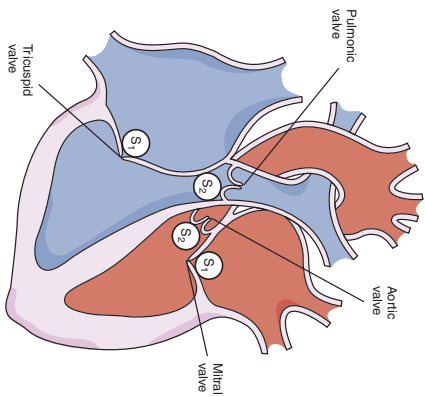
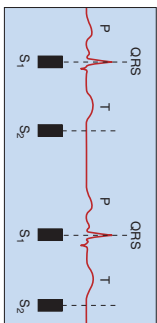
Are the QRS complexes grouped or not grouped?

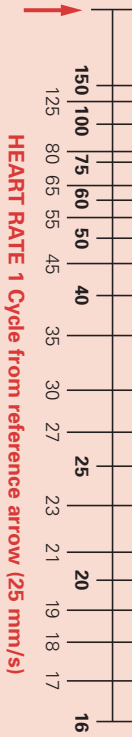Are there any dropped beats?

Is there a compensatory or noncompensatory pause?


QT interval: _____

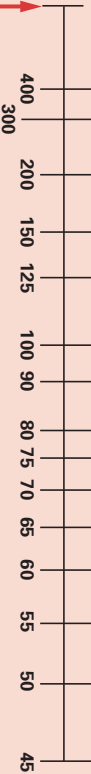Interpretation: _____



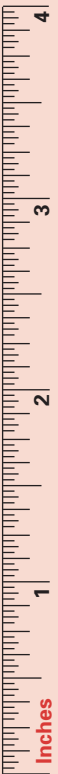


HEART RATE 2 Cycles from reference arrow (25 mm/s)





HEART RATE 3 Cycles from reference arrow (25 mm/s)



Abbreviations

ACE	angiotensin-converting enzyme
ACLS	advanced cardiac life support
ACS	acute coronary syndrome
AED	automatic external defibrillator
A-fib	atrial fibrillation
A-flutter	atrial flutter
AV	atrioventricular
BBB	bundle branch block
BP	blood pressure
bpm	beats per minute
BUN	blood urea nitrogen
CHF	congestive heart failure
CO	cardiac output
COPD	chronic obstructive pulmonary disease
CPR	cardiopulmonary resuscitation
CT	computed tomography
ECG	electrocardiogram
EMD	electromechanical dissociation
ET	endotracheal
FAB	fragment antigen binding
gtt	drops
HR	heart rate
HTN	hypertension
IHSS	idiopathic hypertrophic subaortic stenosis
IM	intramuscular
IO	intraosseous
IV	intravenous
LA	left arm
LL	left leg
LMA	laryngeal mask airway
LOC	level of consciousness
MAT	multifocal atrial tachycardia
MCL	modified chest lead
MI	myocardial infarction
NSR	normal sinus rhythm

201

PAC	premature atrial contraction
PALS	pediatric advanced life support
PAT	paroxysmal atrial tachycardia
PEA	pulseless electrical activity
PJC	premature junctional contraction
PO	by mouth
PSVT	paroxysmal supraventricular tachycardia
PVC	premature ventricular contraction
QTc	QT interval corrected for heart rate
RA	right arm
RL	right leg
SA	sinoatrial
SV	stroke volume
SVT	supraventricular tachycardia
TKO	to keep open
VF	ventricular fibrillation
VT	ventricular tachycardia
WAP	wandering atrial pacemaker
WPW	Wolff-Parkinson-White (Syndrome)

Selected References

1. American Heart Association: Basic Life Support for Healthcare Providers (Student Manual). American Heart Association, Dallas, TX, 2006.
2. American Heart Association: Guidelines for Cardiopulmonary Resuscitation and Emergency Cardiovascular Care. Supplement to Circulation 112: (24), December 13, 2005.
3. Deglin, JH, Vallerand, AH: Davis's Drug Guide for Nurses, ed 9. F. A. Davis, Philadelphia, 2006.
4. Jones, SA: Author's personal collection.
5. Jones, SA: ECG Notes, ed 1. F. A. Davis, Philadelphia, 2005.
6. Jones, SA: ECG Success. F. A. Davis, Philadelphia, 2008.
7. Myers, E: RNotes, ed 2. F. A. Davis, Philadelphia, 2006.
8. Myers, E, Hopkins, T: MedSurg Notes. F. A. Davis, Philadelphia, 2004.
9. Scanlon, VC, Sanders, T: Essentials of Anatomy and Physiology, ed 4. F. A. Davis, Philadelphia, 2003.

Illustration Credits

- ECG strips on pages 28, 32–70, 73–78, 152–185 from Jones, SA: Author's personal collection.
- Pages 14, 109, 123 from Myers, E: RNotes, ed 2. F. A. Davis, Philadelphia, 2006.
- Pages 19, 81, 112, 127, 197 from Myers, E, Hopkins, T: MedSurg Notes. F. A. Davis, Philadelphia, 2004.
- Pages 11, 22 adapted from Myers, E, Hopkins, T: MedSurg Notes. F. A. Davis, Philadelphia, 2004.
- Pages 2, 3, 4, 5, 6, 7, 8 from Scanlon, VC, Sanders, T: Essentials of Anatomy and Physiology, ed 4. F. A. Davis, Philadelphia, 2003.
- Pages 10, 12, 13 from Jones, SA: ECG Success. F. A. Davis, Philadelphia, 2008.

Note: Page numbers followed by “f” and “t” indicate figures and tables, respectively.

A

- Abbreviations, 200–201
- Accelerated idioventricular rhythm, 53
- Accelerated junctional rhythm, 48, 48f
- ACE (angiotensin-converting enzyme) inhibitors, 94
- ACLS. *See* Advanced cardiac life support
- Acute coronary syndrome (ACS), ACLS for, 134–135
- Adenosine, 94–95
- Advanced cardiac life support (ACLS), 128
 - for acute coronary syndrome, 134–135
 - for asystole, 132–133
 - for narrow complex tachycardia, 139–140
 - for pulseless electrical activity, 130–131
 - for sinus bradycardia, 136
 - for stroke, 143–144
 - for unstable tachycardia, 137–138
 - for ventricular fibrillation/pulseless ventricular tachycardia, 128–129
 - for wide complex tachycardia, 141–142
- Agonal rhythm, 52, 176f, 190
- Airway obstruction, management of
 - in conscious adult/child, 122, 122f
 - in conscious infant, 123, 123f
 - positions for, 127f
 - in unconscious adult, 124
 - in unconscious child, 125
 - in unconscious infant, 126
- Amiodarone, 95–96
- Angiotensin-converting enzyme (ACE) inhibitors, 94
- Arrest, sinus, 36, 36f
- Arrhythmias, classification of, 30t
- Arteries
 - coronary, 5f
 - major, 7f
- Artifacts, 77
 - baseline varies with respiration, 77f
 - loose electrodes, 77f
 - muscle, 78f
 - sinus rhythm with, 180f, 191
 - sinus tachycardia with, 183f, 191
 - 60-cycle interference, 78f
- Aspirin, 96
- Asystole, 65, 65f, 156f, 186
 - P wave, 162f, 187
 - PALS for, 148
- Atrial arrhythmias, 38–46
- Atrial contraction, premature (PAC), 40
- Atrial fibrillation (A-fib), 45, 45f, 162f, 175f, 187, 190
- Atrial flutter (A-flutter), 44, 44f, 153f, 186
- Atrial pacemaker, wandering (WAP), 38, 38f
- Atrial tachycardia, 41, 41f
 - multifocal (MAT), 39

- Atrioventricular (AV) blocks, 66–70
 first-degree, 66, 66f
 second-degree
 type I, 67, 67f, 170f, 189
 type II, 68, 68f, 168f, 188
 third-degree, 69, 69f, 172f, 189
- Atrioventricular (AV) node, 11f, 11t
- Atropine sulfate, 96–97
- AV blocks. *See* Atrioventricular blocks
- AV (atrioventricular) node, 11f, 11t
- B**
- Bag-valve-mask, 127f
- BBB. *See* Bundle branch block
- Beta blockers, 97
- Bigeminy, ventricular, 56f
 sinus bradycardia with, 165f, 188
- Block(s). *See* Atrioventricular blocks;
 Bundle branch block; Sinoatrial block
- Bradycardia
 junctional, 177f, 190
 PALS for, 149
- Bundle branch block (BBB), 70, 70f
 left, 92, 92f
 right, 93, 93f
 sinus bradycardia with, 160f, 187
- Bundle branches, 11f, 11t
- Bundle of His, 11f, 11t
- C**
- Cables
 monitoring connections, 194t
 patient, 195
- Calcium chloride, 97–98
- Cardiac cells, properties of, 9t
- Cardiopulmonary resuscitation (CPR)
 of adult, 119
 of child, 120
 health-care providers guidelines for, 118t
 of infant, 121
 positions for, 127f
- Cardiovascular system, anatomy of, 6, 6f
 major arteries, 7f
 major veins, 8f
- Cardioversion, 114
- Carotid sinus message, 116–117, 116f
- Chest leads
 electrode placement, 19f, 20f
 with 3-wire cable, 20f
 with 5-wire cable, 20f
 elements of, 19t
 15-lead, 23, 23t
 electrode placement, 23f
 modified, 21
 electrode placement, 21f
 right-sided 12-lead, 22, 22f, 22t
- Choking. *See also* Airway obstruction, management of
 universal sign of, 127f
- Cincinnati Prehospital Stroke Scale, 144t
- Complex, definition of, 25t
- CPR. *See* Cardiopulmonary resuscitation
- D**
- Defibrillation, 110
 automated external, 112–113
 manual, 110–112
- Deflections, description of, 25t
- Depolarization/depolarization process, 12f
 progression through heart, 13f
 repolarization and, correlation with ECG, 14f
- Digoxin, 98

Digoxin immune FAB, 98–99
 Diltiazem, 99
 Dopamine, 99–100
 Dropped beats, characteristics
 of, 29t

E

ECG. *See* Electrocardiogram
 Electrical activity, definitions, 25t
 Electrical axis deviation, 82, 82f
 Electrocardiogram (ECG), 15
 chest leads in, 19f, 19t, 20t, 21t
 correlation of depolarization/
 repolarization with, 14f
 15-lead, 23, 23f, 23t
 interpretation of, 29t–30t
 leads used in, 16–18, 16f
 limb leads in, 16–18, 16f, 17f, 17t,
 18f, 18t
 monitoring cable connections,
 194t
 patient record of, 195–196
 recording of, 24f
 tracing components, 24f
 troubleshooting, 194
 12-lead, 80, 82
 normal tracing, 86f
 right-sided, 22, 22f, 22t

Electrodes

loose, 170f, 189
 placement of, 19f
 15-lead, 23f
 with 5-wire cable, 20f
 modified chest leads, 21f
 standard limb leads, 16f
 with 3-wire cable, 20f

Epinephrine, 100

F

Fibrillation. *See* Atrial fibrillation;
 Ventricular fibrillation

Fibrinolytic agents, 100–101
 Five-wire telemetry units, 20
 Furosemide, 101

G

Glasgow Coma Scale, 145t

H

Head tilt-chin lift position, 127f
 Heart
 anatomy of, 1, 1f
 chambers/great vessels, 4f
 coronary arteries/veins, 5f
 tissue layers, 2, 2f
 valves, 3f
 conduction system of, 11f
 electrophysiology, 11t, 12t
 physiology of, 9
 mechanics of heart
 function, 9t
 properties of cardiac cells, 9t
 systolic/diastolic phases, 10f
 progression of depolarization
 through, 13f
 Heart rate
 calculation of, 26–28, 26f, 27t, 28f,
 198f, 199f
 characteristics of, 29t
 normal, 30t
 Heart sounds, 197f

I

Ibutilide, 101–102
 Idioventricular rhythm, 52, 52f,
 152f, 186
 accelerated, 53, 53f
 Infarction. *See* Myocardial
 infarction
 Internodal pathways, 11f, 11t
 Interval, definition of, 25t
 Ischemia, 83, 83f, 83t

- Isoproterenol, 102
- IV fluid drip rates, 108t
and drug amounts, universal formula for, 109
- J**
- Jaw thrust maneuver, 127f
- Junctional arrhythmias, 47–51
- Junctional escape beat, 50, 50f
- Junctional rhythm, 47, 47f, 174f, 190
- Junctional tachycardia, 49, 49f
- L**
- Leads, 15. *See also* Chest leads; Limb leads
- Left bundle branch block, 92, 92f
- Lidocaine, 102–103
- Limb leads
augmented, 18
elements of, 18t
standard, 17, 17f
electrode placement, 16, 16f
elements of, 17t
- M**
- Magnesium sulfate, 103–104
- MAT (multifocal atrial tachycardia), 39, 39f
- Medications, 94–107
ACE inhibitors, 94
adenosine, 94–95
amiodarone, 95–96
aspirin, 96
atropine sulfate, 96–97
beta blockers, 97
calcium chloride, 97–98
common formulas, 108
digoxin, 98
digoxin immune FAB, 98–99
diltiazem, 99
dopamine, 99–100
epinephrine, 100
fibrinolytic agents, 100–101
furosemide, 101
ibutilide, 101–102
isoproterenol, 102
lidocaine, 102–103
magnesium sulfate, 103–104
morphine sulfate, 104
nitroglycerin, 104–105
oxygen, 105
procainamide, 105–106
sodium bicarbonate, 106
vasopressin, 106–107
verapamil, 107
- MI. *See* Myocardial infarction
- Mobitz I AV block, 67, 67f
- Mobitz II AV block, 68, 68f
- Morphine sulfate, 104
- Multifocal atrial tachycardia (MAT), 39, 39f
- Myocardial infarction (MI)
acute, progression of, 84, 84f
anterior, 87, 87f
inferior, 88, 88f
lateral, 89, 89f
location of, by ECG leads, 83t
posterior, 91, 91f
septal, 90, 90f
- N**
- Nitroglycerin, 104–105
- Normal sinus rhythm (NSR), 32, 32f, 178f, 190
- O**
- Obstruction, airway. *See* Airway obstruction, management of
- Oxygen, therapeutic, 105

- P**
- P wave, 25t
 - asystole, 162f, 187
 - characteristics of, 29t
 - on ECG tracing, 24f
 - sinus tachycardia with, 185f, 192
 - PAC. *See* Premature atrial contraction
 - Pacemaker(s)
 - artificial
 - codes, 72
 - modes, 71
 - rhythm, 72
 - types of, 71
 - atrial, with 100% capture, 172f, 189
 - atrioventricular, 180f, 191
 - failure to capture, 75f, 176f, 190
 - failure to capture underlying rhythm asystole, 168f, 188
 - failure to sense, 76f
 - malfunctions of, 75t
 - oversensing, 76f
 - Pacemaker rhythms, 72
 - dual-chamber, 74f
 - single-chamber, 73f
 - PALS. *See* Pediatric advanced life support
 - Paroxysmal supraventricular tachycardia (PSVT), 43, 43f, 158f, 187
 - Pediatric advanced cardiac life support (PALS)
 - for asystole, 148
 - for pulseless electrical activity, 147
 - for ventricular fibrillation/pulseless ventricular tachycardia, 146
 - Pediatric advanced life support (PALS)
 - for bradycardia, 149
 - for unstable narrow QRS tachycardia, 150
 - Pericardium, 2, 2f
 - PR interval, 25t
 - characteristics of, 29t
 - on ECG tracing, 24f
 - Premature atrial contraction (PAC), 40, 40f
 - Premature junctional contraction, 51, 51f
 - Premature ventricular contraction (PVC), 54, 54f
 - couplets, 57f, 171f, 189
 - interpolated, 59, 59f
 - multiform, 55f
 - R-on-T phenomenon, 58, 58f
 - sinus rhythm with, 163f, 187
 - uniform, 55f
 - ventricular bigeminy, 56f
 - ventricular quadrigeminy, 57f
 - ventricular trigeminy, 56f
 - Procainamide, 105–106
 - PSVT. *See* Paroxysmal supraventricular tachycardia
 - Pulseless electrical activity (PEA), 64, 64f
 - ACLS for, 130–131
 - PALS for, 147
 - Purkinje system, 11f, 11t
 - PVC. *See* Premature atrial contraction
- Q**
- QRS complex, 25t
 - on ECG tracing, 24f
 - QRS interval, 29t
 - on ECG tracing, 24f
 - QT interval, 25t
 - on ECG tracing, 24f
 - Quadrigeminy, ventricular, 57f

R

- R wave, 25t
 - on ECG tracing, 24f
 - progression of, 81, 81f
- Resuscitation. *See* Cardiopulmonary resuscitation
- Rhythm(s). *See also* Arrhythmias
 - accelerated idioventricular, 53, 53f
 - accelerated junctional, 48, 48f
 - agonal, 176f, 190
 - analysis of, 29t
 - junctional, 47, 47f, 174f, 190
 - pacemaker, 72
 - dual-chamber, 74f
 - single-chamber, 73f
 - sinus
 - with multiform PVCs, 171f, 189
 - with muscle artifacts, 180f, 191
 - normal (NSR), 32f, 178f, 190
 - with premature junctional contractions, 179f, 190
 - with ST segment depression, 184f, 192
 - with ST segment elevation, 182f, 191
 - with two premature atrial contractions, 181f, 191
 - with two SA blocks, 184f, 192
 - with ventricular trigeminy, 178f, 190
- Right bundle branch block, 93, 93f
- R-on-T phenomenon, 58, 58f
- R-R interval, 26, 26f

S

- Segment, definition of, 25t
- Sinoatrial (SA) block, 37, 37f
- Sinoatrial (SA) node, 11f, 11t
- Sinoatrial (SA) node arrhythmias, 32–37

- Sinus arrhythmia, 35, 35f
 - Sinus bradycardia, 33, 33f, 152f, 186
 - ACLS for, 136
 - with bundle branch block, 160f, 187
 - with first-degree AV block, 161f, 187
 - with ventricular bigeminy, 165f, 188
 - Sinus pause (sinus arrest), 36, 36f
 - sinus rhythm with, 160f, 187
 - Sinus rhythm
 - with multiform PVCs, 171, 189
 - with muscle artifacts, 180f, 191
 - normal (NSR), 32f, 178f, 190
 - with premature junctional contractions, 179f, 190
 - with ST segment depression, 184f, 192
 - with ST segment elevation, 182f, 191
 - with two premature atrial contractions, 181f, 191
 - with two SA blocks, 184f, 192
 - Sinus tachycardia, 34, 34f, 156f, 186
 - with muscle artifacts, 183f, 191
 - with P prime wave, 185f, 192
 - Sodium bicarbonate, 106
 - ST segment, 25t
 - on ECG tracing, 24f
 - elevation/depression of, 85, 85f
 - Stroke
 - ACLS for, 143–144
 - assessment of, 144
 - Supraventricular tachycardia (SVT), 42, 42f, 159f, 182f, 187, 191
- T**
- T wave, 25t
 - on ECG tracing, 24f

- Tachycardia. *See also* Sinus tachycardia; Supraventricular tachycardia
 narrow complex with stable regular rhythm, ACLS for, 139–140
 unstable, ACLS for, 137–138
 unstable narrow QRS, PALS for, 150–151
 wide complex with stable regular rhythm, ACLS for, 141–142
- Torsade de pointes, 62, 62f, 169f, 188
- Trigeminy, ventricular, 56f
 sinus rhythm with, 178f, 190
- U**
- U wave, 25t
 on ECG tracing, 24f
 sinus rhythm with, 164f, 188
- Universal formula, for drip rates and medication amounts, 109
- Universal sign of choking, 127f
- V**
- Vasopressin, 106–107
- Veins
 coronary, 5f
 major, 8f
- Ventricular arrhythmias, 52–65
- Ventricular fibrillation (VF), 63, 63f, 155f, 173f, 186, 189
 ACLS for, 128–129
 PALS for, 146
 polymorphic, 174f, 190
- Ventricular tachycardia (VT)
 monomorphic, 60, 60f, 157f, 164f, 166f, 167f, 186, 188
 polymorphic, 61, 61f
 pulseless
 ACLS for, 128–129
 PALS for, 146
 torsade de pointes, 169f, 188
- Verapamil, 107
- VF. *See* Ventricular fibrillation
- VT. *See* Ventricular tachycardia
- W**
- Wandering atrial pacemaker (WAP), 38, 38f
- Wave. *See also specific type*
 definition of, 25t
- Wenckebach AV block, 67, 67f
- Wolff-Parkinson-White (WPW) syndrome, 46, 46f